

OPHTHALMOLOGY

Clinical Report

Renata K. Nogueira

Mariana Fauster

CACD, male, 31 years, HbSC, diagnosis of sickle cell disease at the age of 12

Baseline hematological data:

Hb: 13.0 g/dL

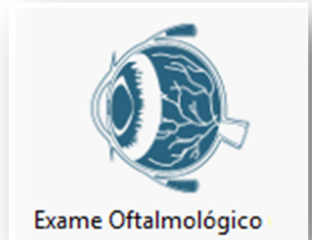WBC: 6800/mm³

O₂ saturation: 99%

Past history:

- Sparse pain crisis
- Avascular necrosis of the right femoral neck

OPHTHALMOLOGY



- **Ocular complaints:** none
- **Past ophthalmic history:** unremarkable
- **Visual acuity**
 - **OD:** 20/20 -0.75
 - **OS:** 20/20 -1,25
- **Intraocular pressure**
 - **OU:** 12 mmHg

OPHTHALMOLOGY



▪ Biomicroscopy

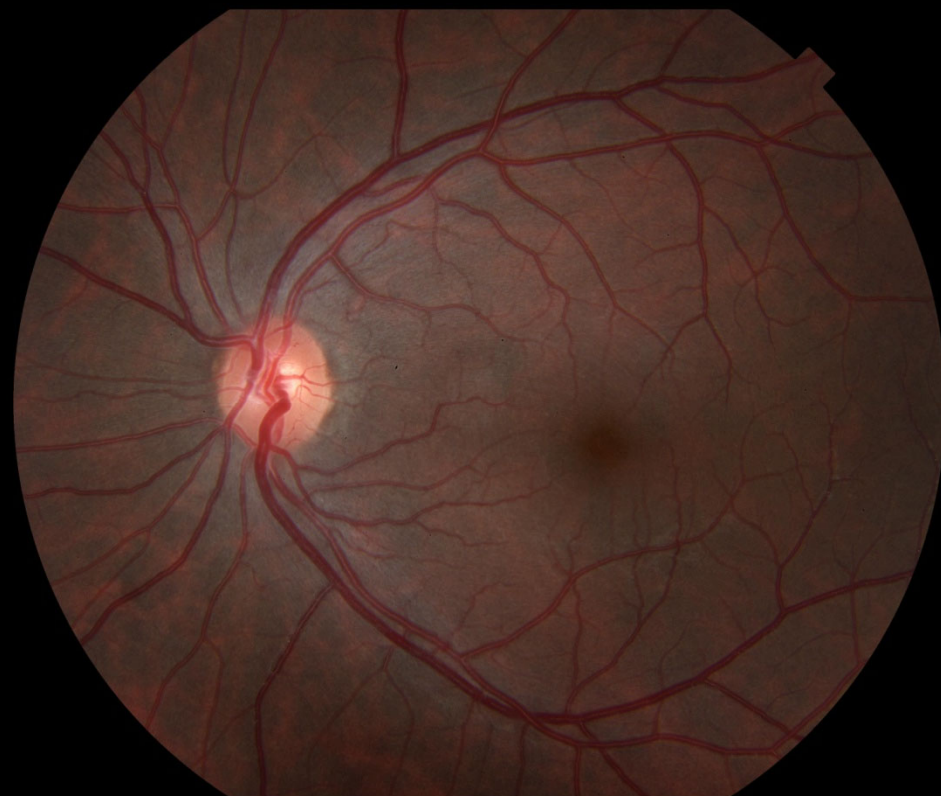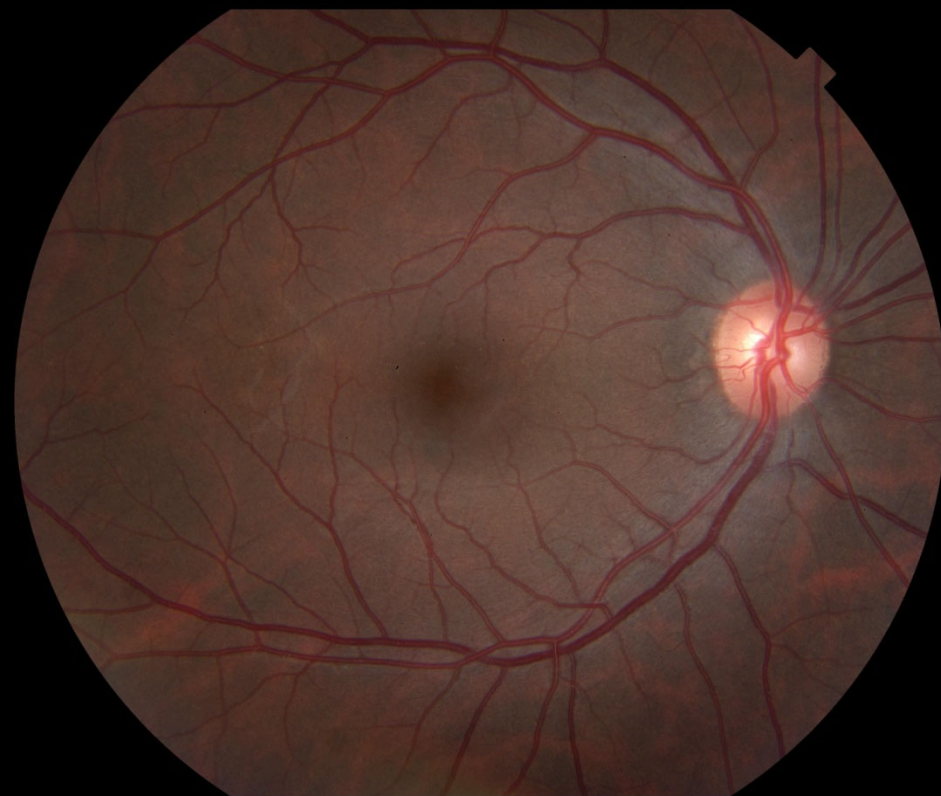- **Eyelids:** Within normal limits (WNL)
- **Conjunctivae:** Quiet, mild vascular tortuosity OU
- **Corneas:** Clear
- **Anterior chambers:** Clear
- **Irises:** WNL
- **Lenses:** Clear
- **Anterior vitreous:** Clear

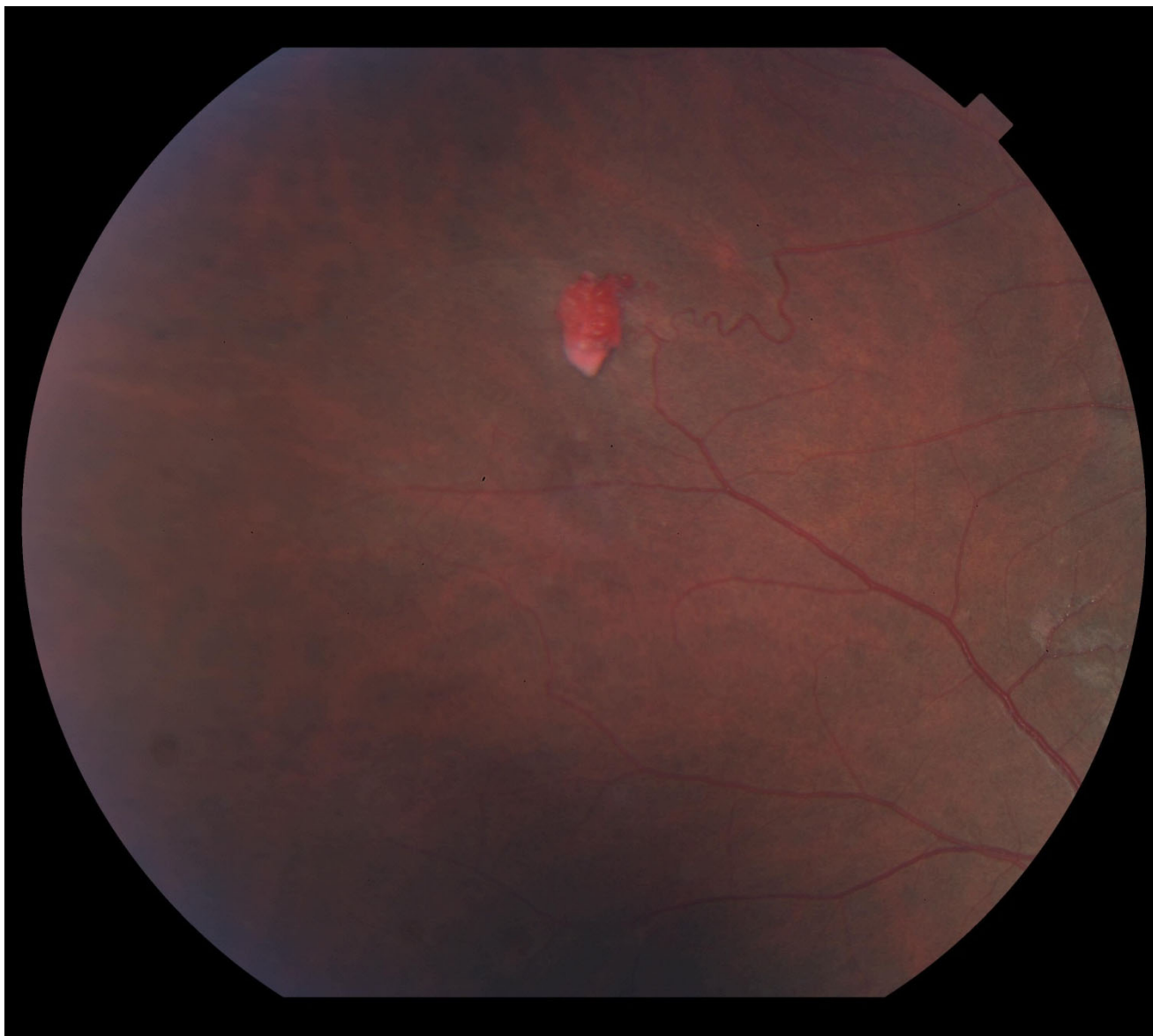OPHTHALMOLOGY

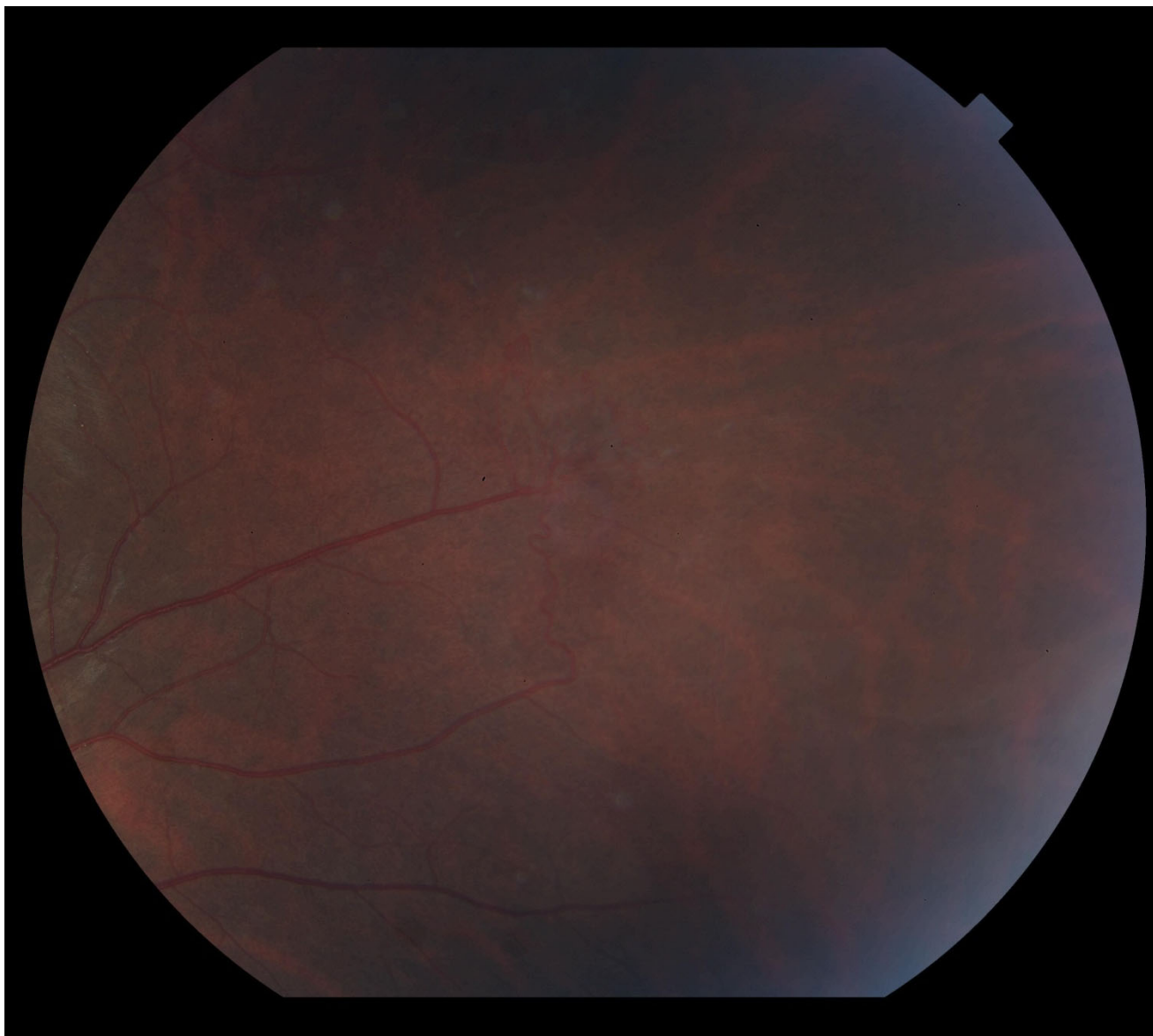


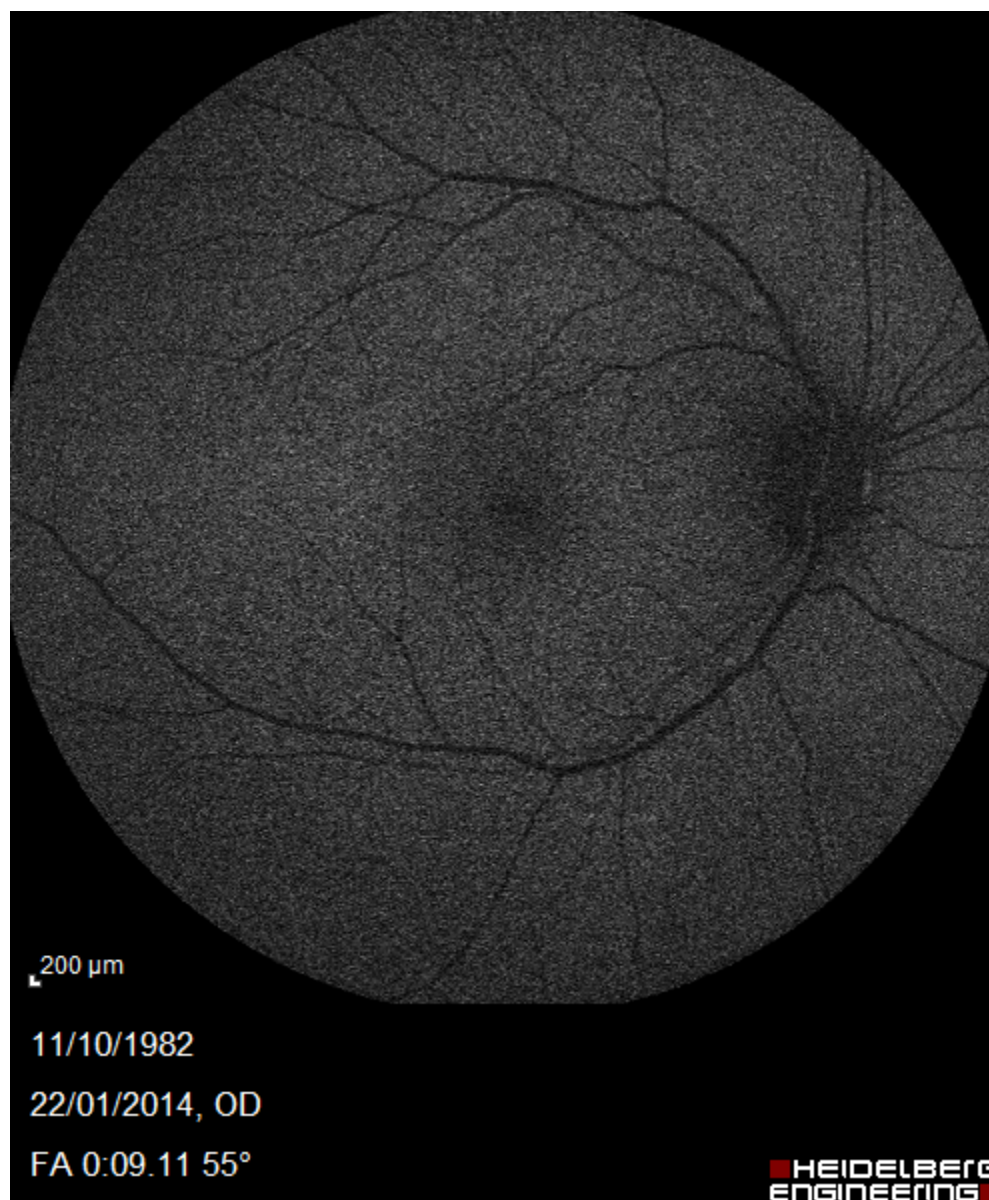▪ Fundus

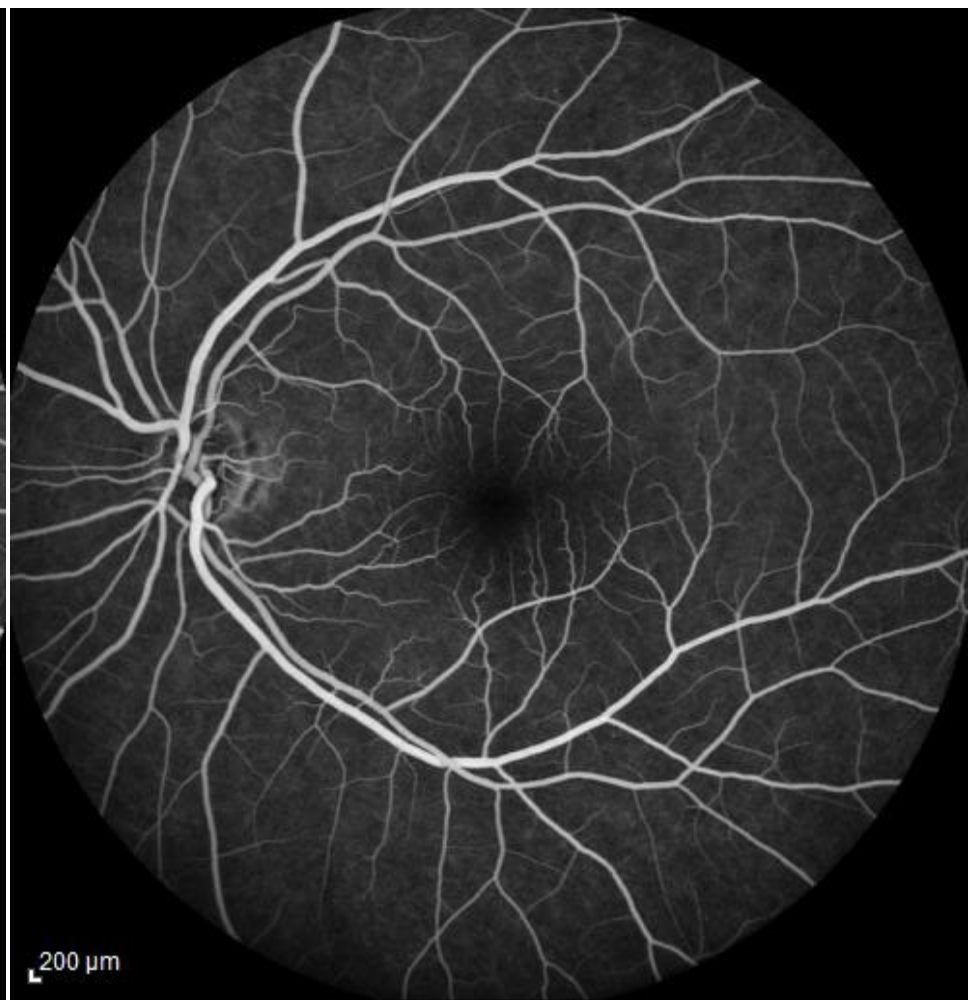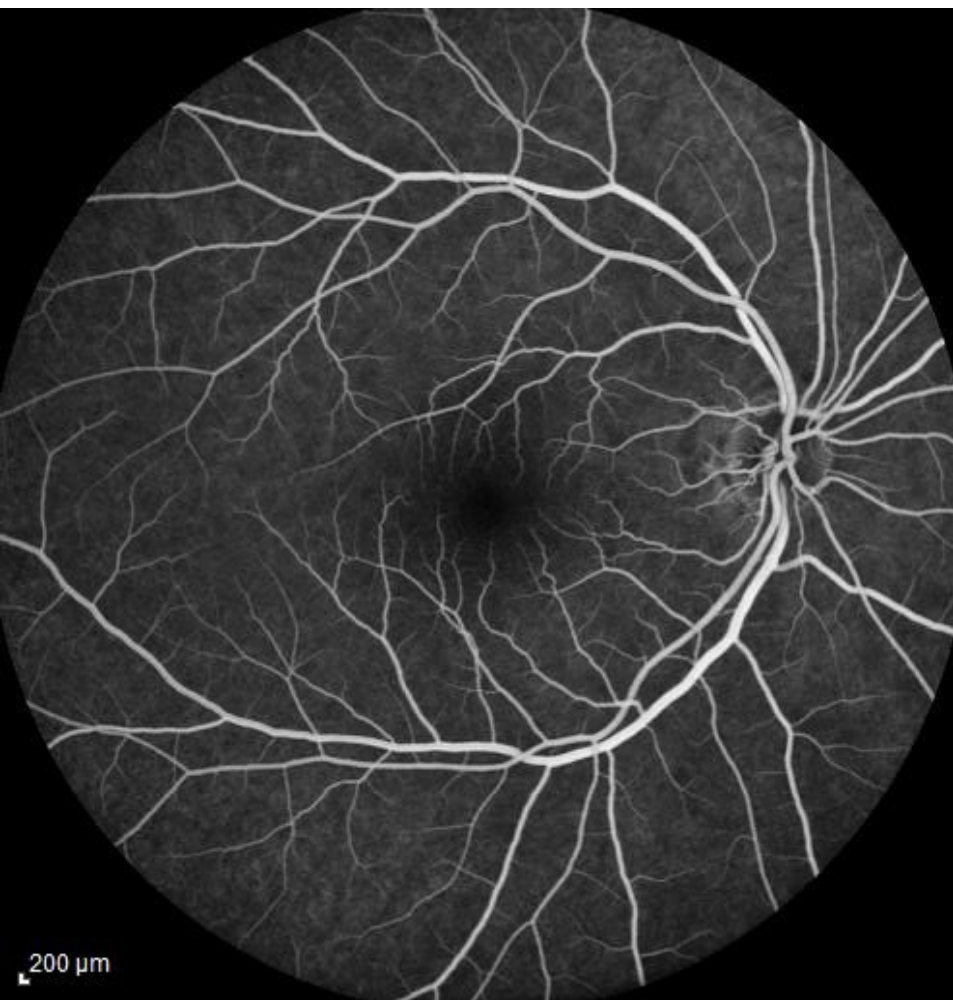
- Normal posterior pole OU
- Peripheral vascular occlusions and anastomoses in OU, with formation of seafans at the interface of normal/ischemic retina

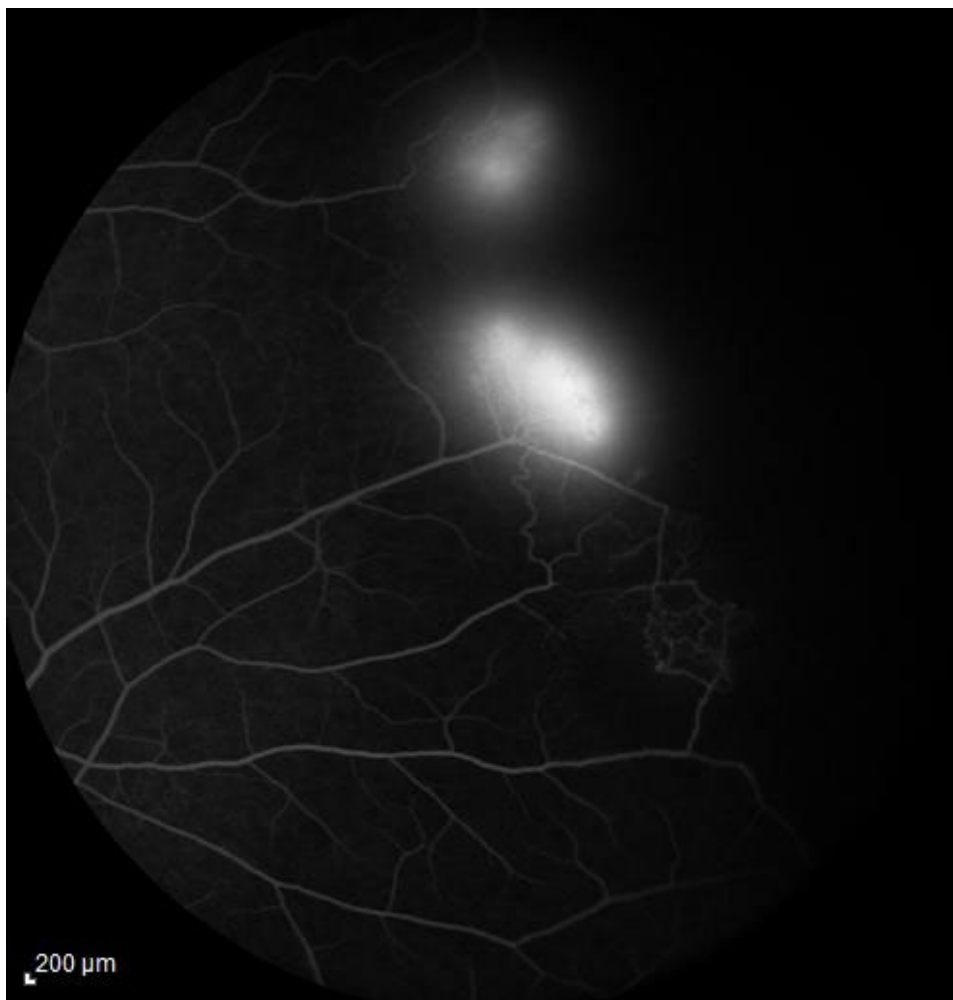
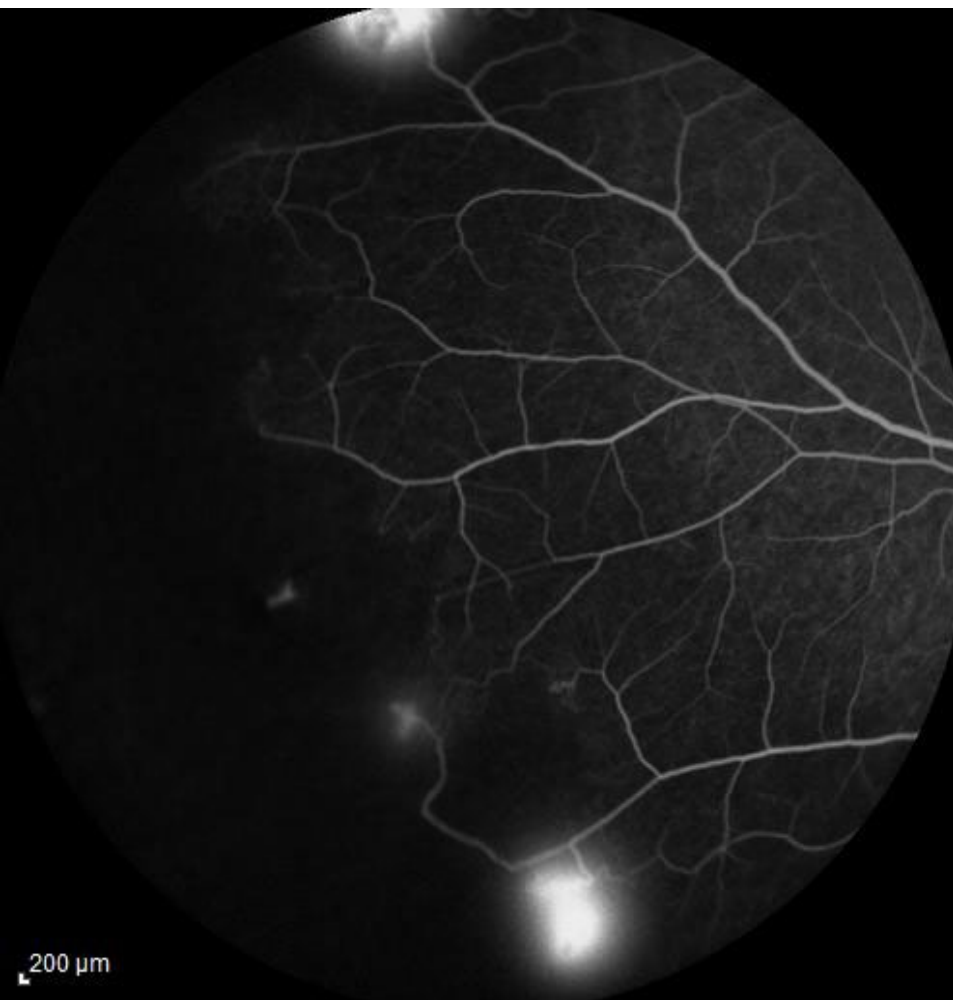
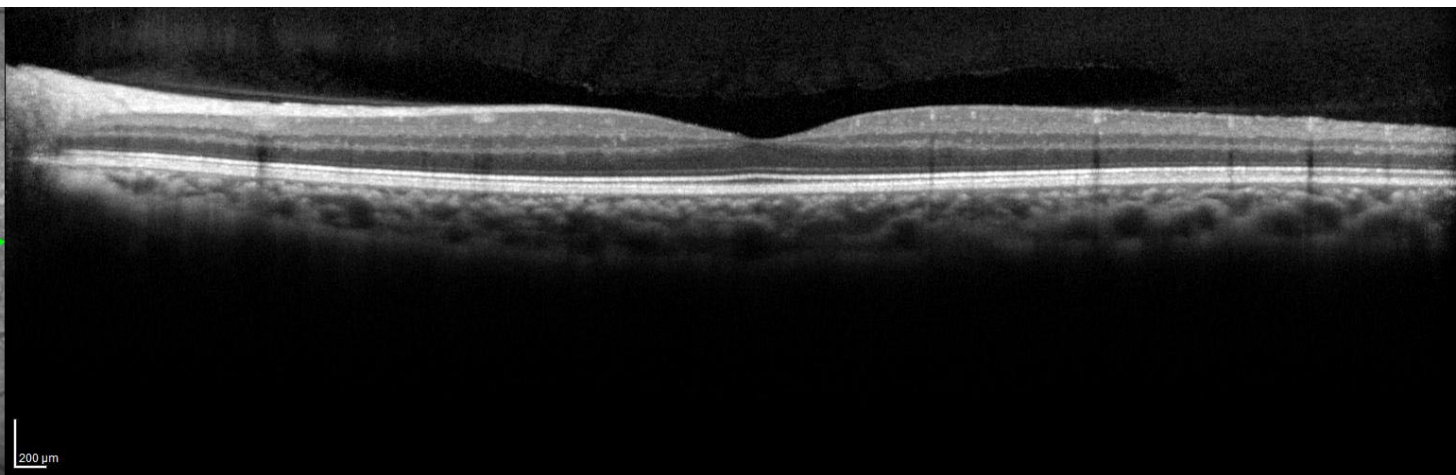
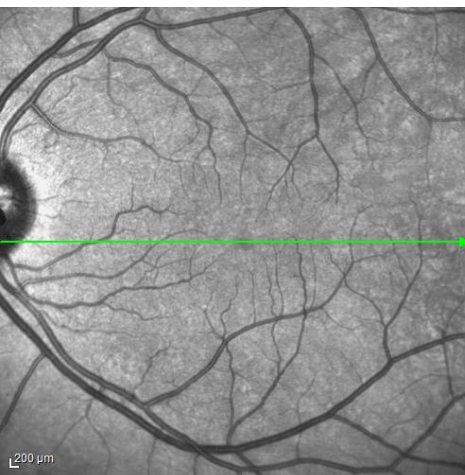
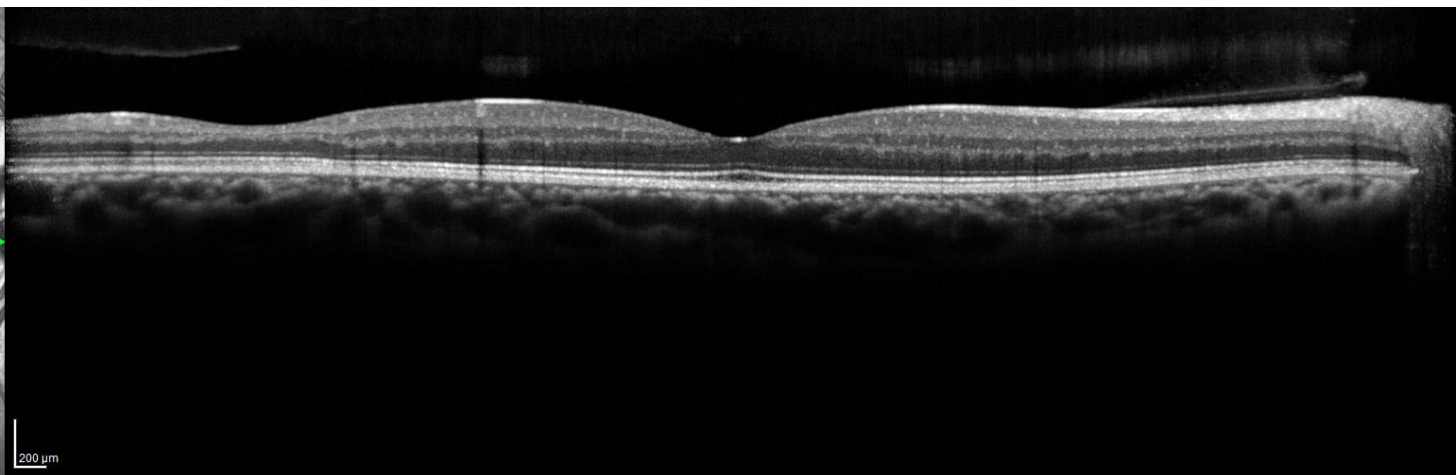
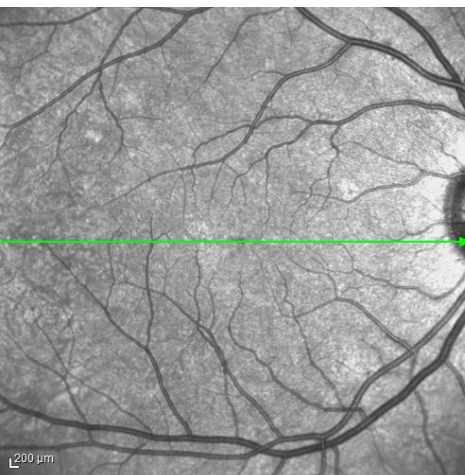


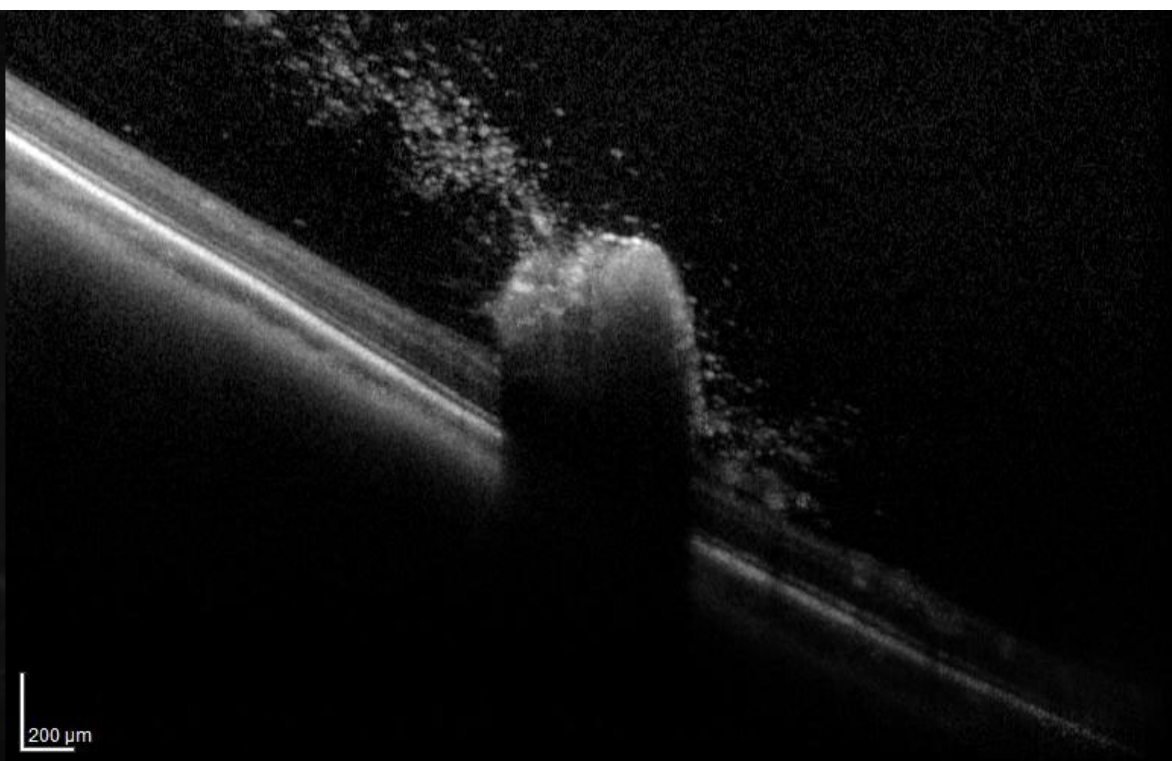


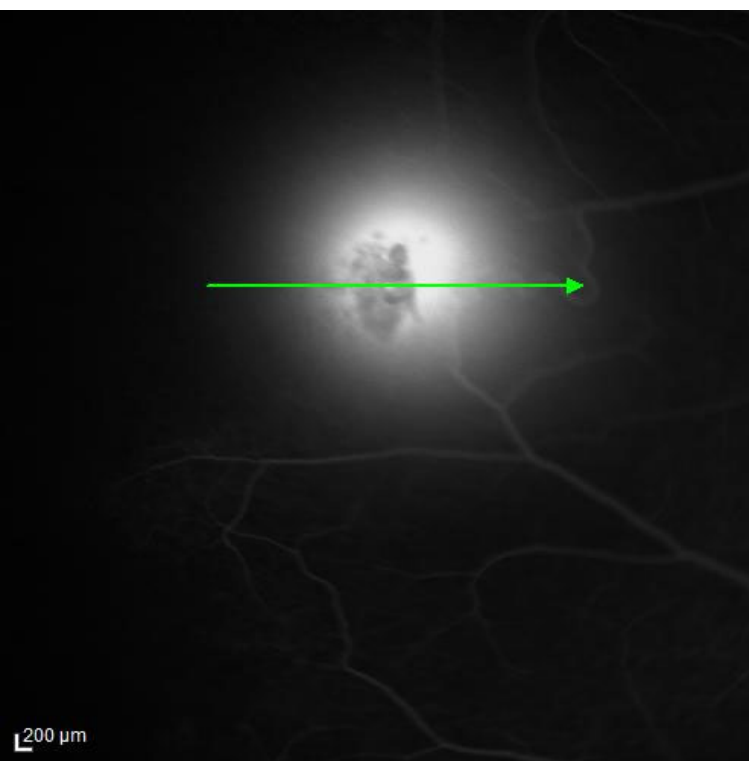









11/10/1982

22/01/2014, OD

OPHTHALMOLOGY

- **Diagnosis**

- Proliferative sickle cell retinopathy (stage III).
- Mild myopia

- **Treatment:**

- Laser photocoagulation OU

Discussion