OPTHALMOLOGY AND SICKLE CELL DISEASE

– Experience of PAE at the Ophthalmology Clinic –

Daniel Vítor Vasconcelos Santos

Professor Adjunto de Oftalmologia e Pesquisador do NUPAD

Faculdade de Medicina da UFMG

Belo Horizonte – MG

HISTORICAL REMARKS

on. - This showed him to be a young
y hair. He was fairly well developed p
vas a tinge of yellow in the sclera and
The eyes were normal; the pupils sh
ation. The hearing was good; there w

- Herrick, 1910

  "thin, elongated, sickle-shaped and crescent-shaped forms"

- Cook, 1930

  Retinal hemorrhage in sickle cell disease (SCD)

- Pauling et al, 1949

  HbS in SCD



HISTORICAL REMARKS

- Munro & Walker, 1960

  Nine cases of proliferative sickle retinopathy

- Welch & Goldberg, 1966

  Laser photocoagulation for sickle retinopathy

- Goldberg, 1971

  Classification of sickle retinopathy

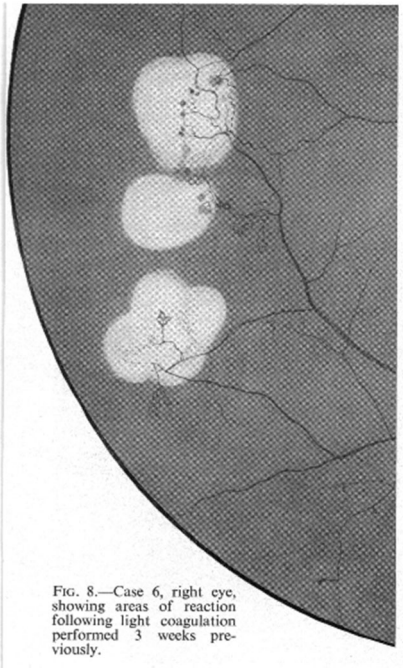

FIG. 8.—Case 6, right eye, showing areas of reaction following light coagulation performed 3 weeks previously.

dvitor@ufmg.br

Protean ocular manifestations of SCD

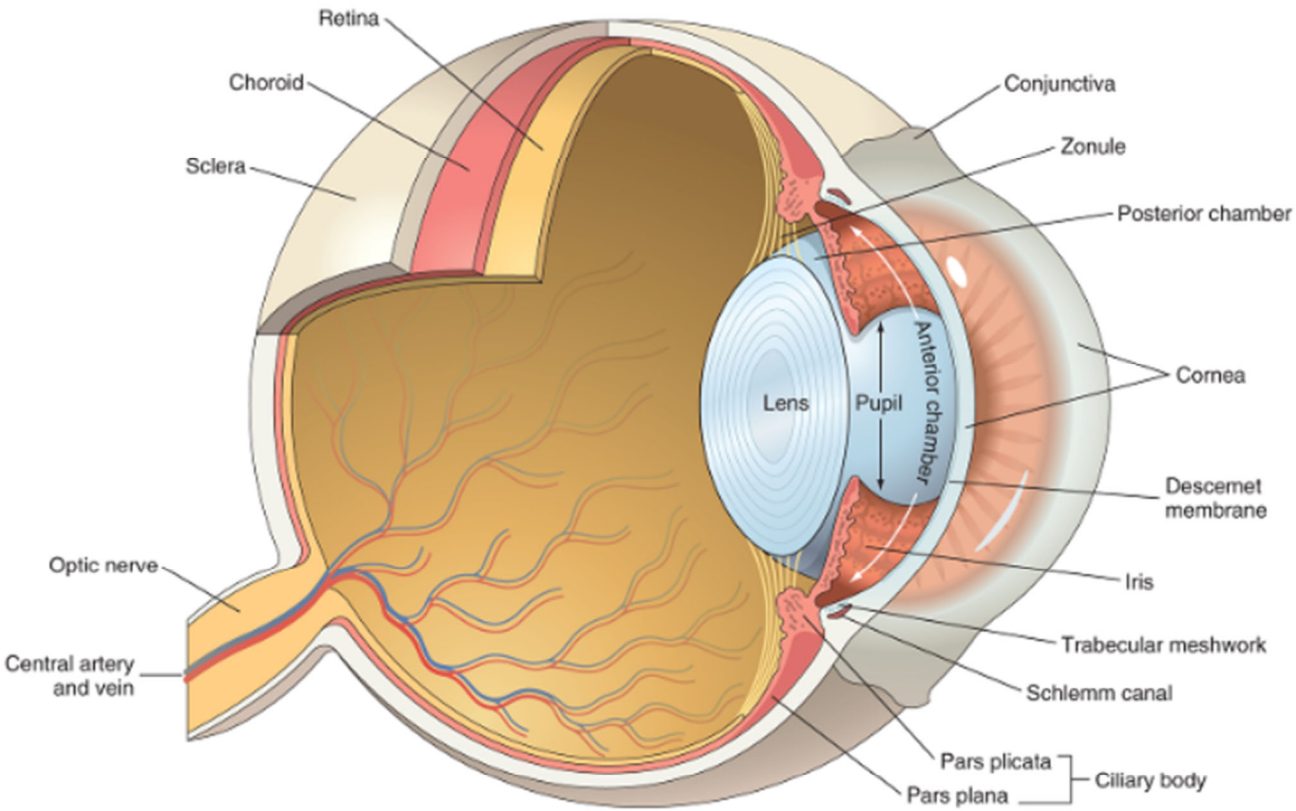

Folberg et al, 2008

SICKLE RETINOPATHY

- Frequent complication of SCD

  ~40% of patients with HbSC

  ~14-20% of patients with HbSS

- Associated with retinal ischemia / neovascularization
- Relative "dissociation" from systemic complications
- Risk of blindness

Condon et al, 1980
Fox et al, 1990
Downes et al, 2005

dvitor@ufmg.br

SICKLE RETINOPATHY

Goldberg classification

- **Stage I:** Peripheral arterial occlusions
- **Stage II:** Peripheral arteriovenous anastomoses
- **Stage III:** Neovascular/glial proliferation *(sea fans)*
- **Stage IV:** Vitreous hemorrhage
- **Stage V:** Retinal detachment

Goldberg, 1971

dvitor@ufmg.br

THERAPY

- Scatter laser photocoagulation
  - Ablation of ischemic retina
  - Prevent progression from stage III to IV and/or V
  - Small unilateral *sea fans* may be closely followed

    Possibility of spontaneous regression (up to 30%)
- Vitreoretinal surgery for selected cases (IV and V)

Rednan et al, 1982
Condon et al, 1984
Williamson et al, 2009

dvitor@ufmg.br

dvitor@ufmg.br

OPHTHALMOLOGY IN PAE

- *Kickoff* in July 2013

  - Wednesday mornings
  - Outpatient Clinic of Hospital São Geraldo / HC-UFMG
  - 68 patients seen

- Software development / customization (EMR)

- Examination / imaging protocols

dvitor@ufmg.br

SOFTWARE CUSTOMIZATION

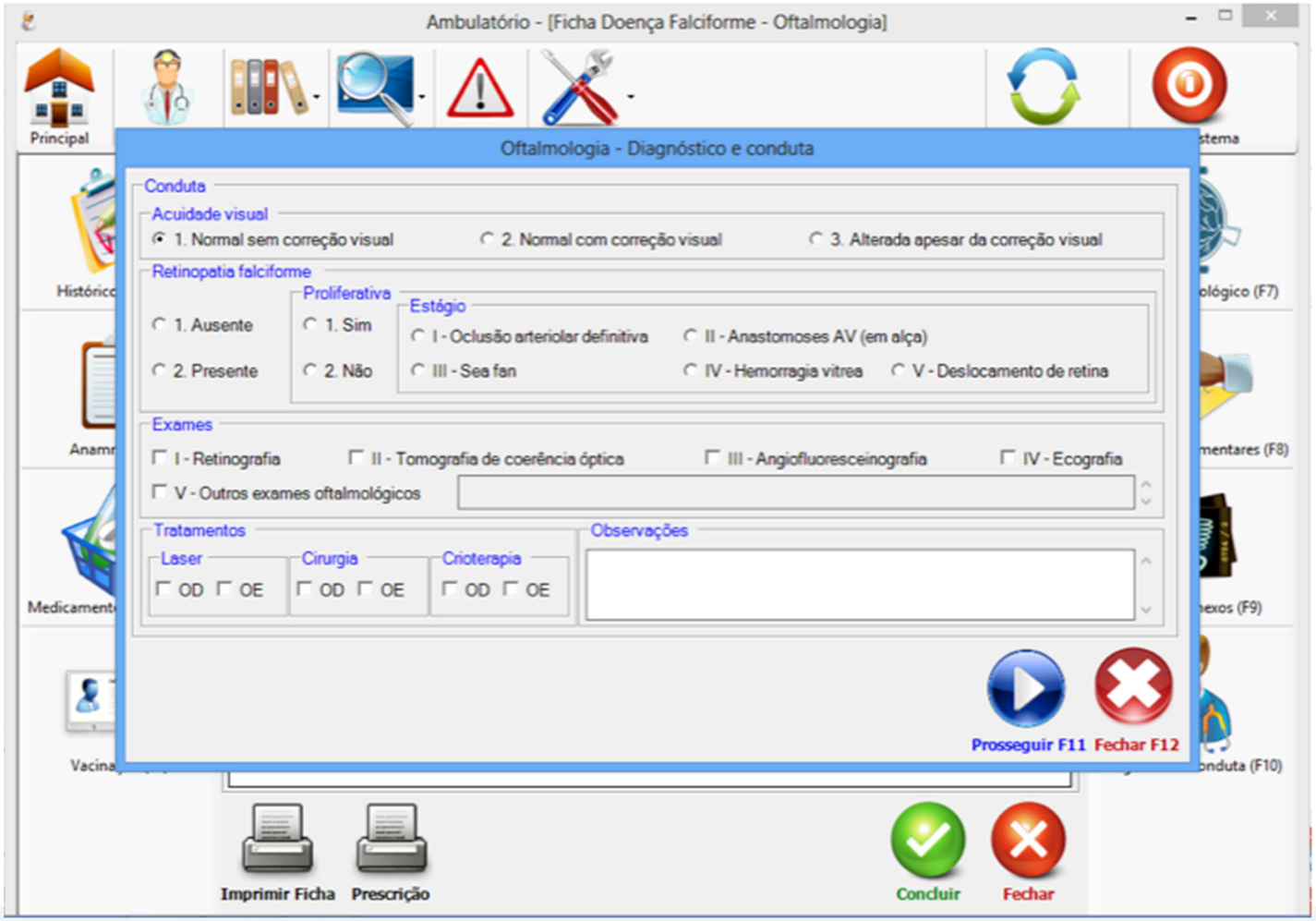

SOFTWARE CUSTOMIZATION

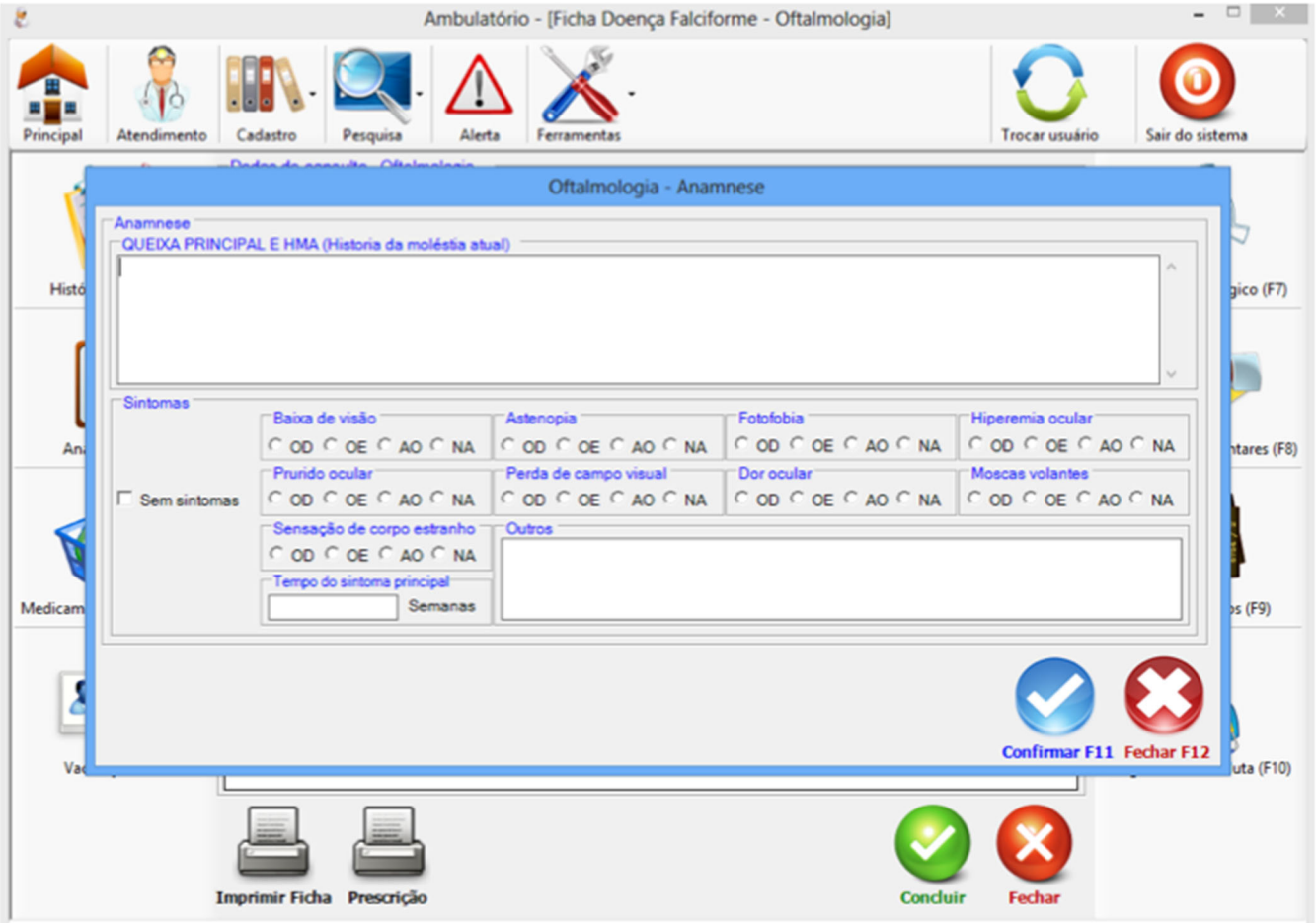

dvitor@ufmg.br

SOFTWARE CUSTOMIZATION

Ambulatório - [Ficha Doença Falciforme - Oftalmologia]

Oftalmologia - Exame Físico

Exame Físico - OD: Normal / Alterado
Exame Físico - OE: Normal / Alterado
Peso g
Altura cm
Frequência respiratória /min
Frequência cardíaca /min
IMC

Ectoscopia
Normal
Alterado
OD
OE
Sinais
Ptose: D / E / Bilat.
Edema palpebral: D / E / Bilat.
Proptose: D / E / Bilat.
Hiperemia ocular: D / E / Bilat.
Pupila
Sem alteração
Alterado

Alinhamento ocular
Normal
Alterado

Motricidade ocular
Normal
Alterado

Acuidade visual
OD: conta-dedos m | MM | PL | SPL | Correção: SC (sem correção) / PH (Pinhole) / CC (com correção) | FQ. ESF. 0+ / 0- . - . x . = 0
OE: conta-dedos m | MM | PL | SPL | Correção: SC (sem correção) / PH (Pinhole) / CC (com correção) | FQ. ESF. 0+ / 0- . - . x . = 0

Tonometria bidigital
OD: Normal / Alto / Baixa
OE: Normal / Alto / Baixa

Tonometria aplanação
OD mmHg
OE mmHg

Biomicroscopia
Fundo de olho
Confirmar F11
Fechar F12

Imprimir Ficha
Prescrição
Concluir
Fechar

dvitor@ufmg.br

SOFTWARE CUSTOMIZATION

Ambulatório - [Ficha Doença Falciforme - Oftalmologia]

Oftalmologia - Exame Físico

Oftalmologia - Exame de Biomicroscopia

Dados (F3) | Continuação (F4)

Biomicroscopia - OD: Normal / Alterado
Biomicroscopia - OE: Normal / Alterado

Pupilas: Sem alteração / Alterado
Pálpebras: Sem alteração / Alterado

Vasos em vírgula: Ausente / OD / OE / AO — Localização
Hiperemia conjuntival: Ausente / OD / OE / AO — Intensidade — Localização

Quemose conjuntival: Ausente / OD / OE / AO
Reação conjuntival: Ausentes — OD: Papilar / Folicular — OE: Papilar / Folicular
Opacidade corneana: Ausente / OD / OE / AO — Localização/Natureza

Precipitados cerásticos: Ausente / OD / OE / AO — Descrição

Flare: Ausente — OD: 1+ 2+ 3+ 4+ — OE: 1+ 2+ 3+ 4+
Atrofia iriana setorial: Ausente — Sim — Localização

Células: Ausente — OD: 0,5+ 1+ 2+ 3+ 4+ — OE: 0,5+ 1+ 2+ 3+ 4+
Hifema: Ausente — Sim — Altura mm
Rubeosis iridis: Ausente / OD / OE / AO

Catarata: Ausente / OD / OE / AO — Grau — Localização
Outros

Células pigmentadas no vítreo anterior: Ausente — OD: Raras 1+ 2+ 3+ 4+ — OE: Raras 1+ 2+ 3+ 4+

Confirmar F11 Fechar F12

dvitor@ufmg.br

SOFTWARE CUSTOMIZATION

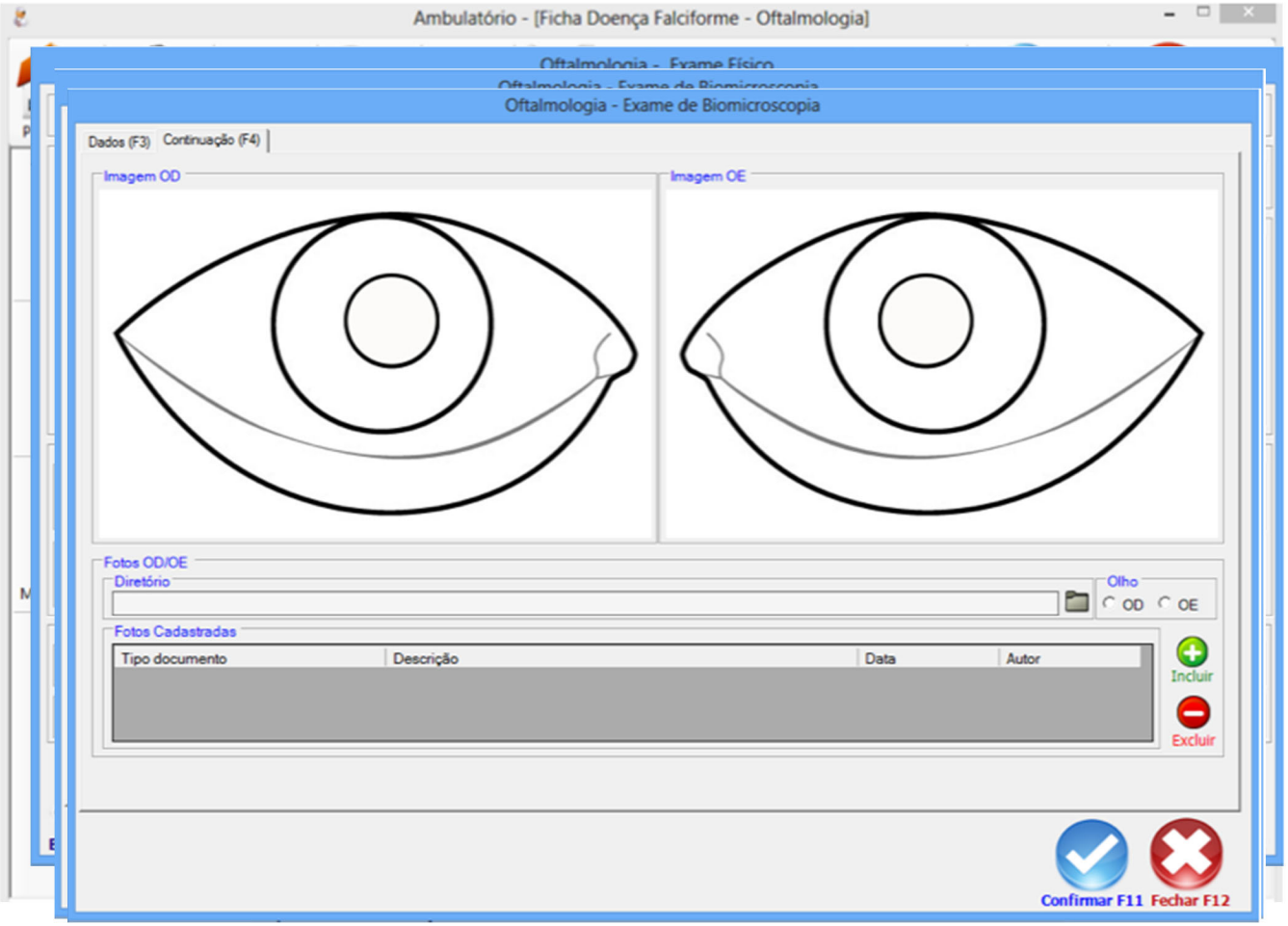

SOFTWARE CUSTOMIZATION

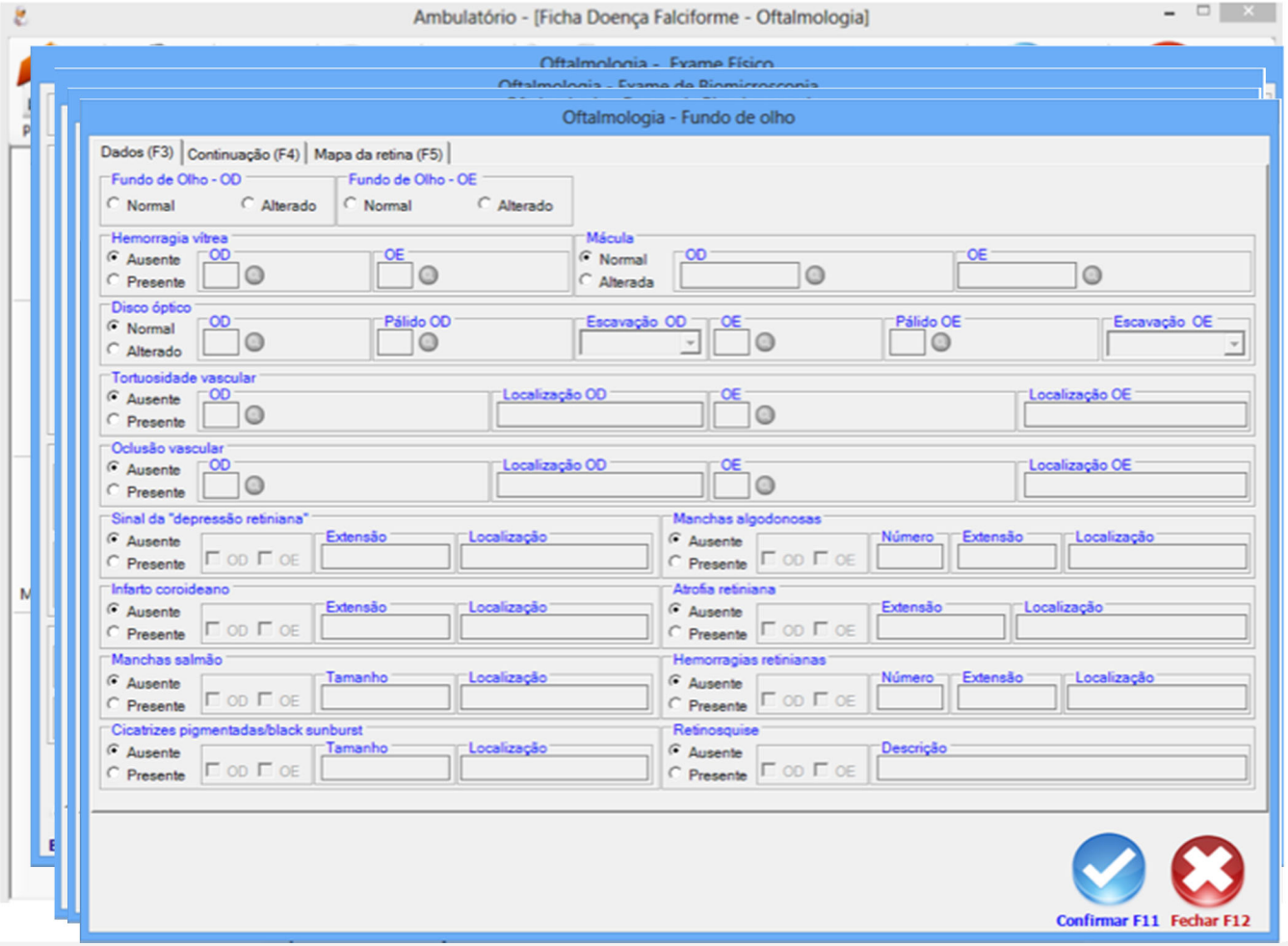

dvitor@ufmg.br

SOFTWARE CUSTOMIZATION

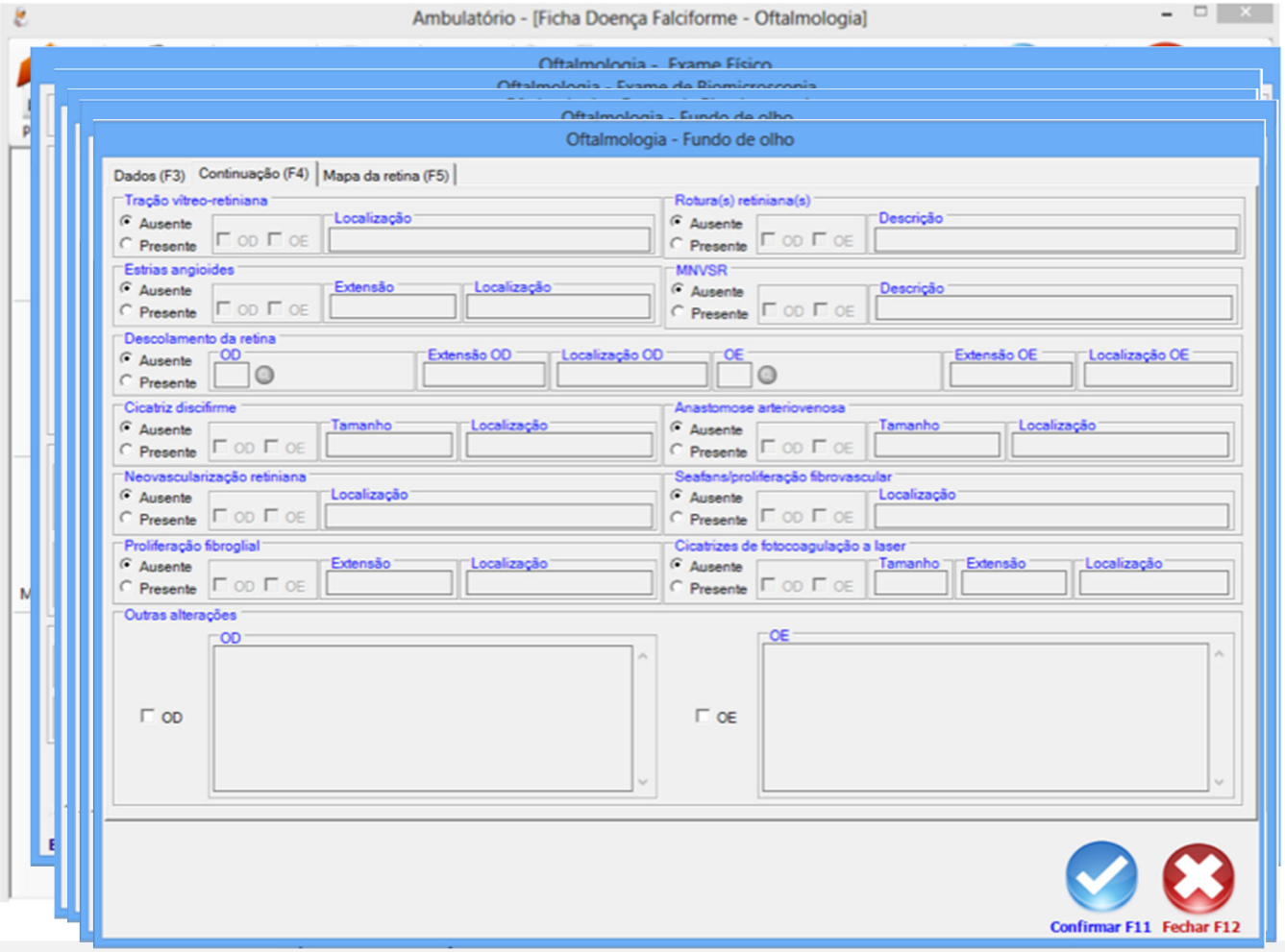

SOFTWARE CUSTOMIZATION

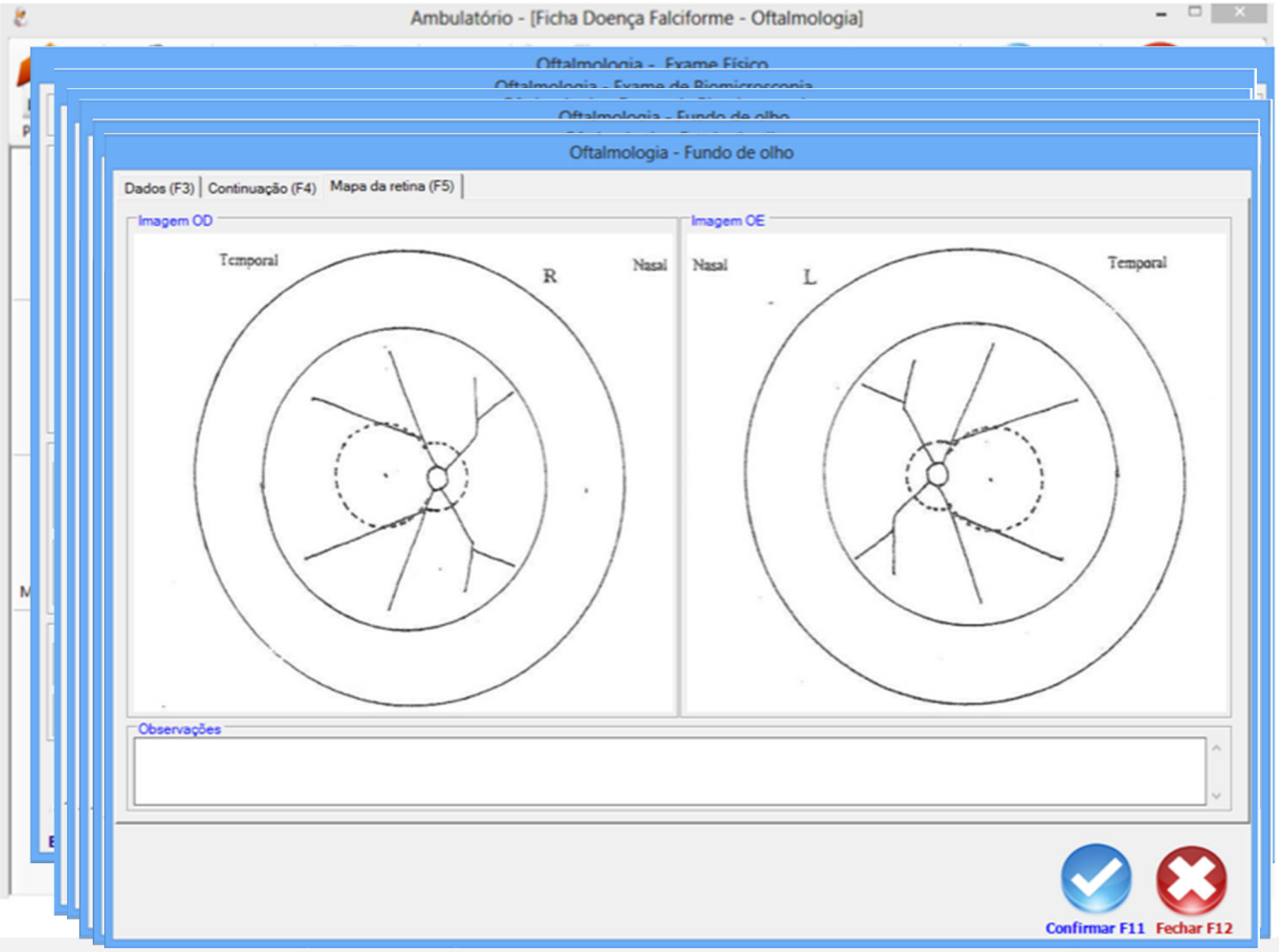

SOFTWARE UTILIZATION

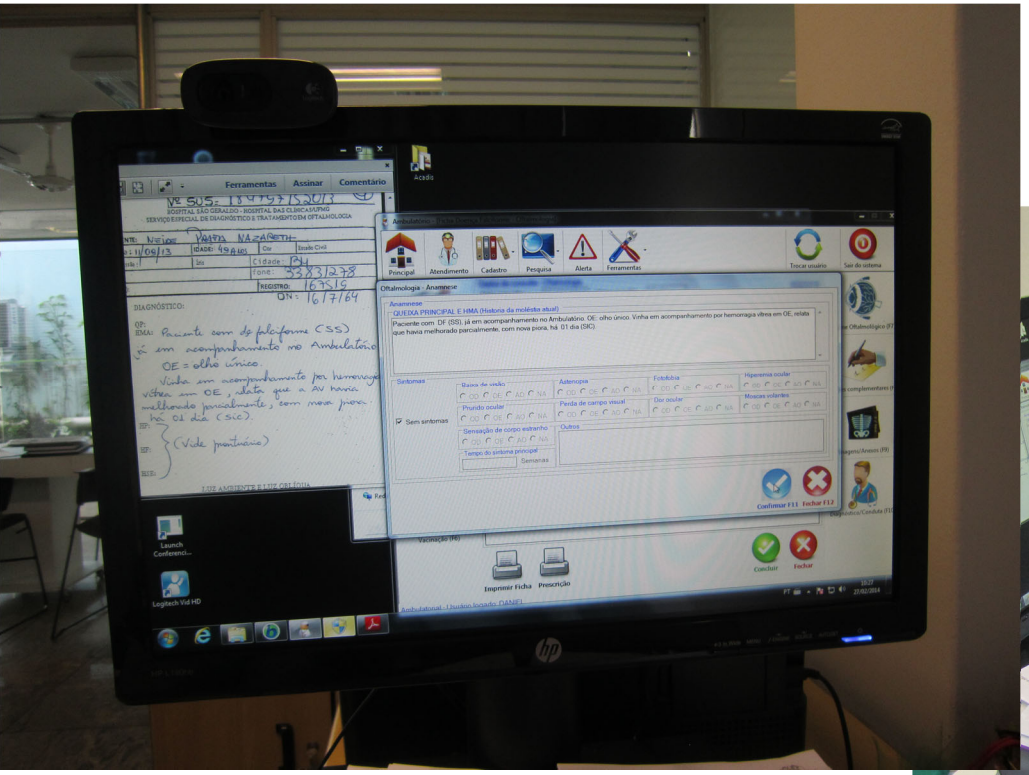

OPHTHALMOLOGIC EXAM

Focus on SCD

- Visual acuity
- Slit lamp biomicroscopy
- Fundus examination (indirect ophthalmoscopy)

Other imaging modalities

- Fundus photography / filters
- Fluorescein angiography
- Optical coherence tomography
- Ultrasonography (B-scan)

dvitor@ufmg.br

OPHTHALMOLOGIC EXAM

VISUAL ACUITY

OPHTHALMOLOGIC EXAM

BIOMICROSCOPY

Slit lamp

dvitor@ufmg.br

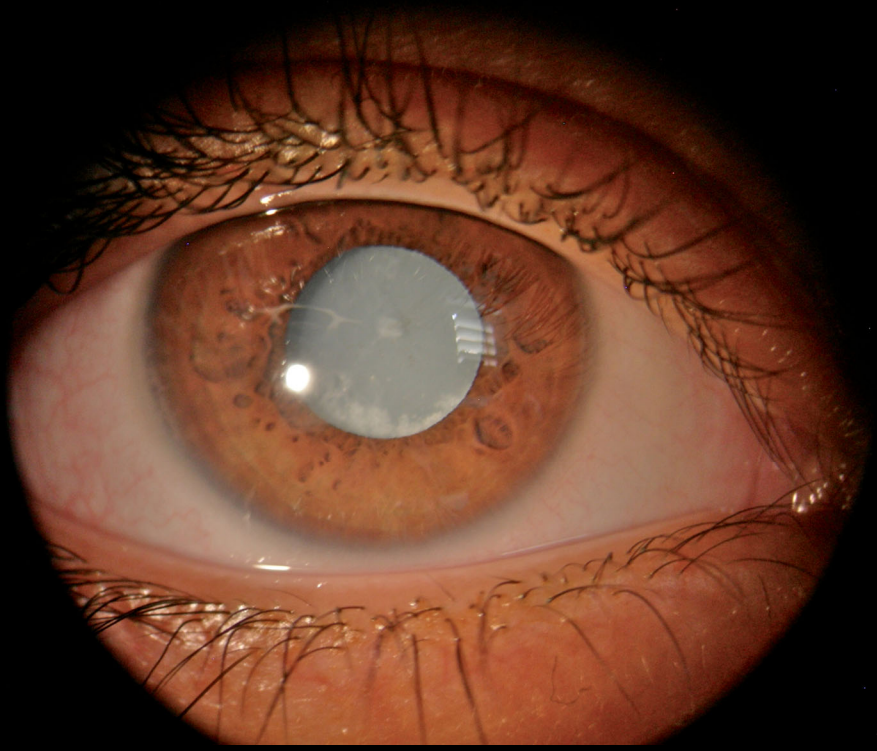

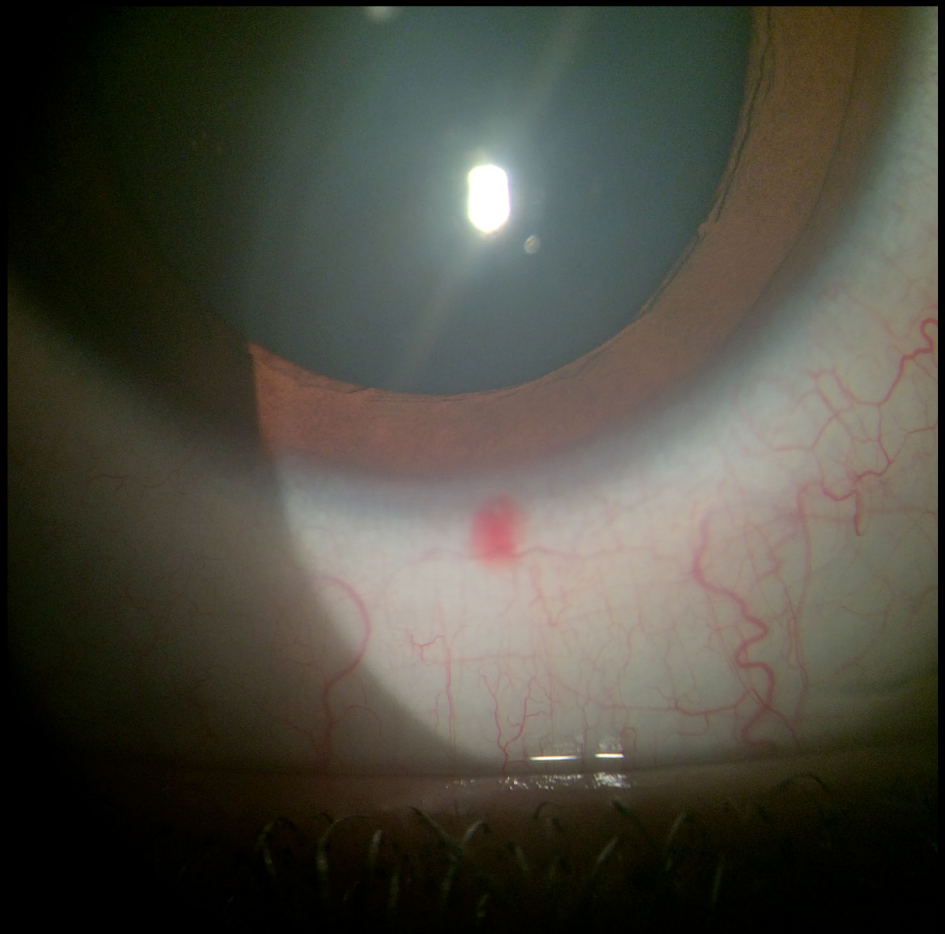

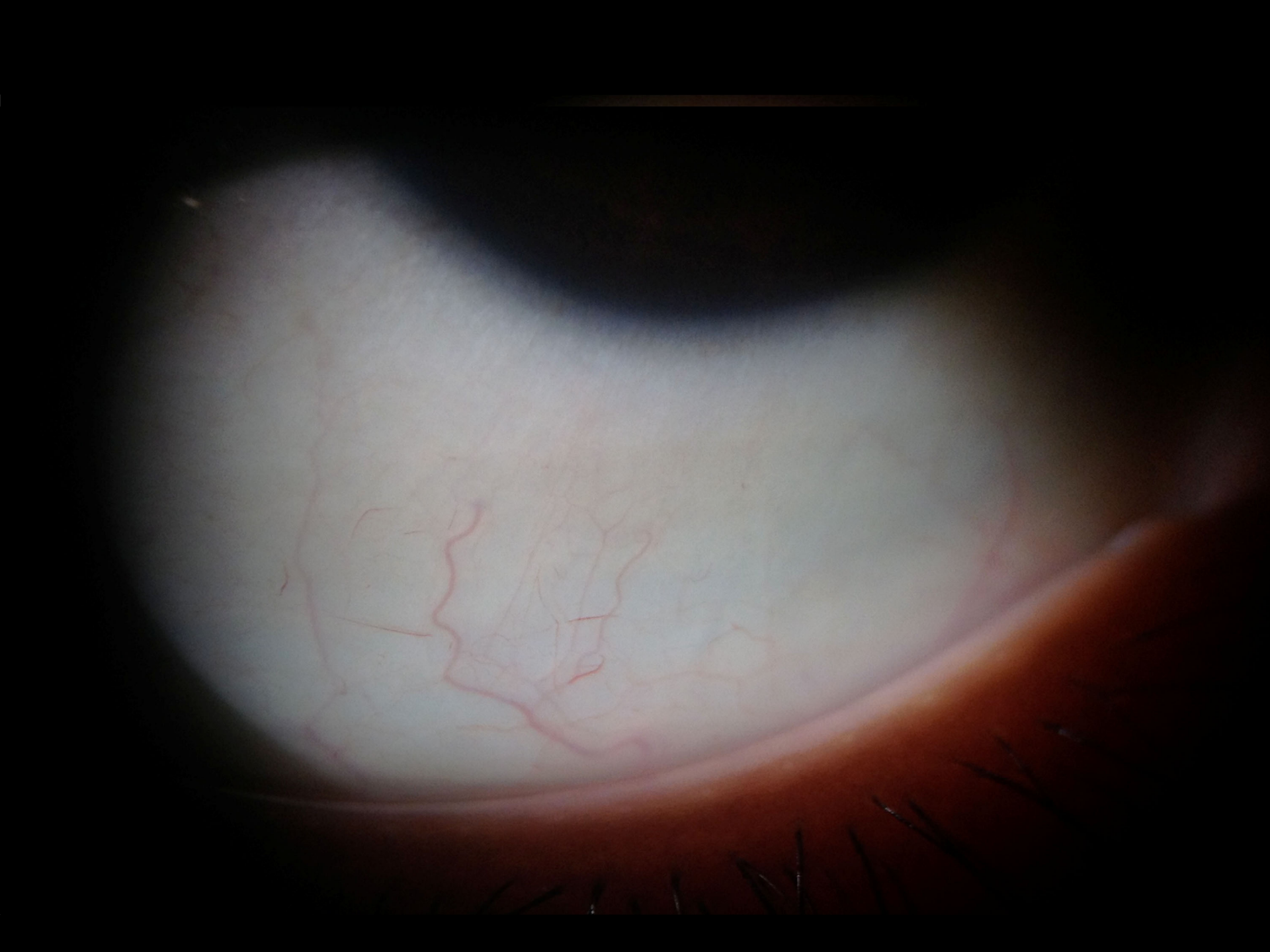

OPHTHALMOLOGIC EXAM

FUNDUS EXAMINATION

Indirect ophthalmoscopy

dvitor@ufmg.br

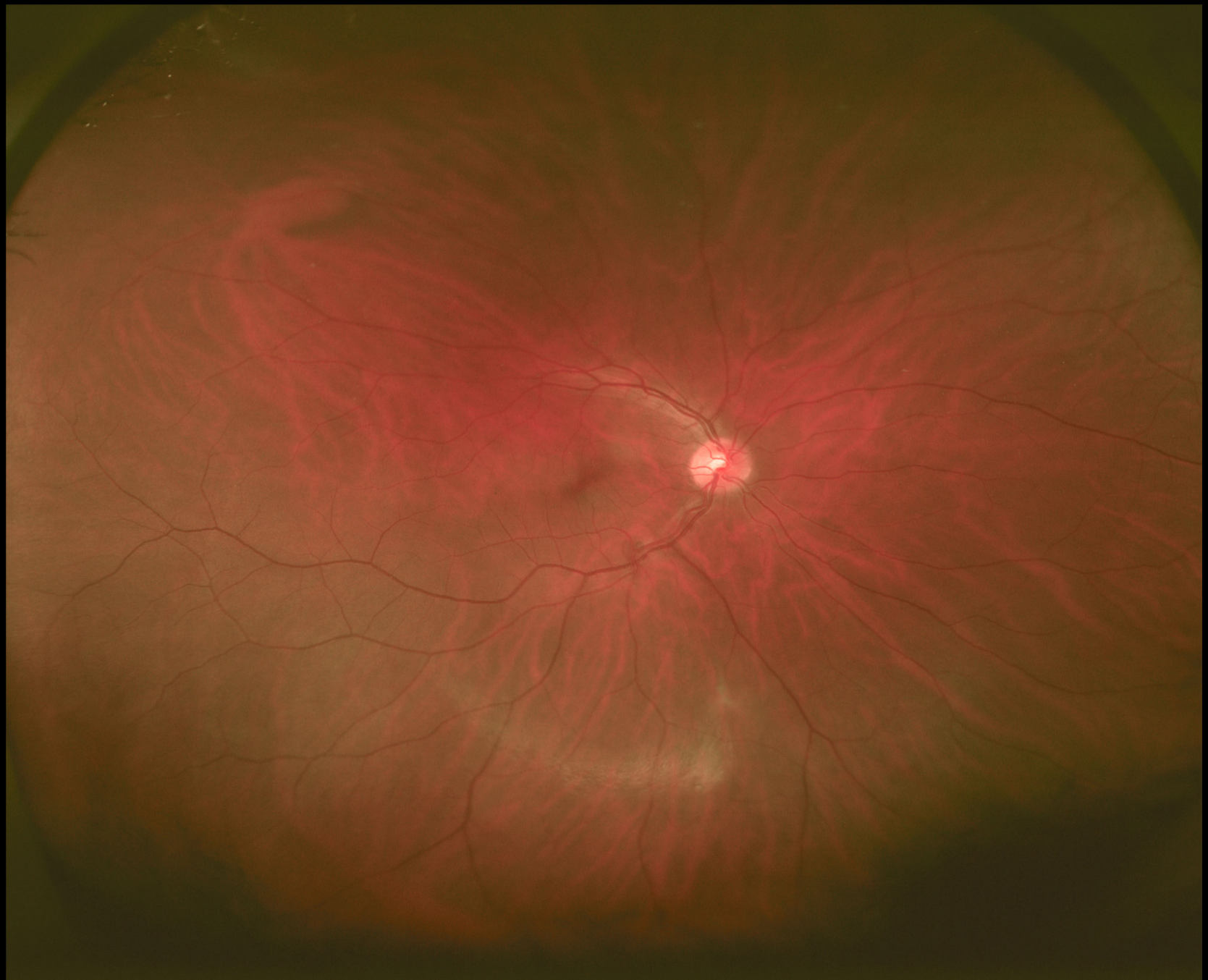

Other imaging modalities

- Fundus photography / filters

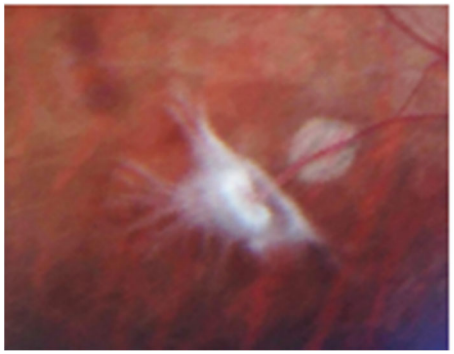

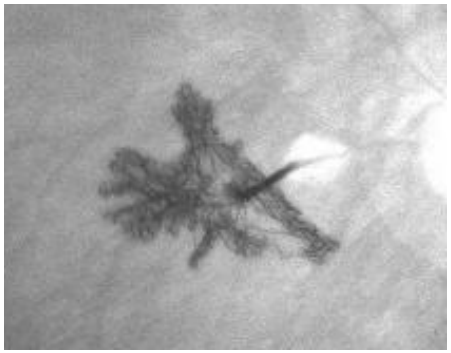

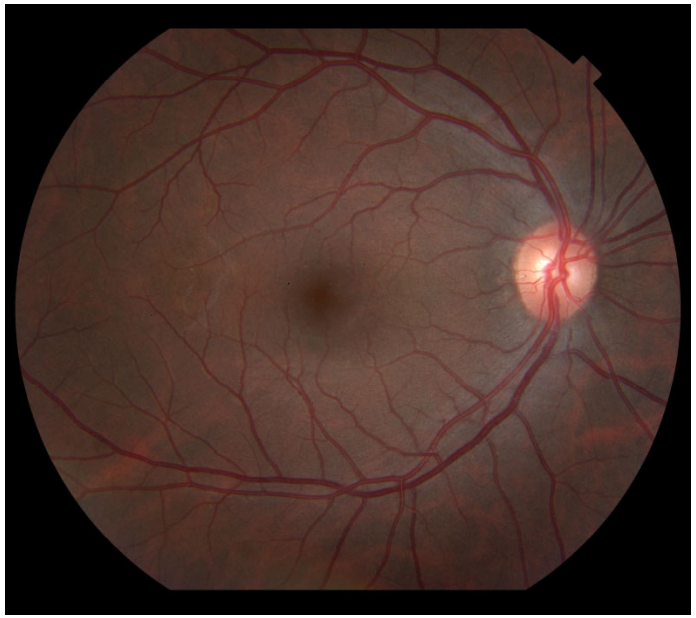

nIR RF nIR-FAF FAF

Other imaging modalities

- Fluorescein angiography

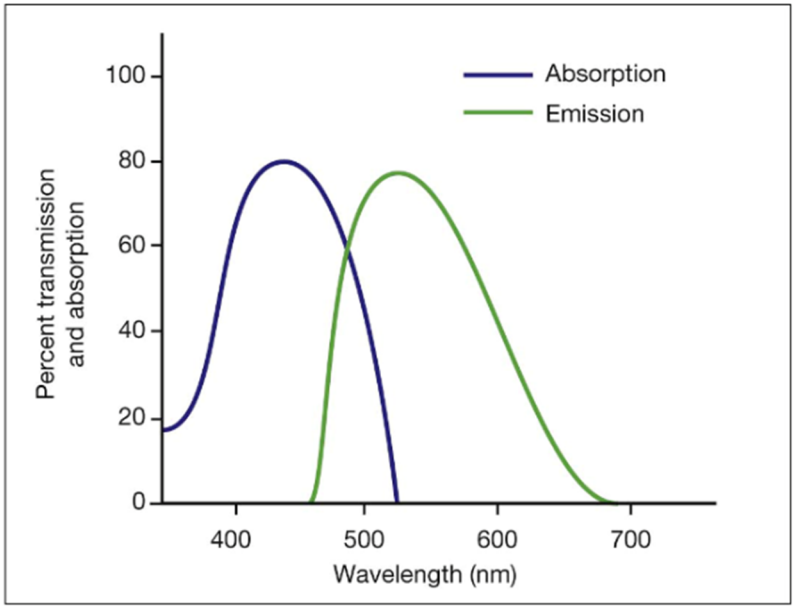

Other imaging modalities

- Fluorescein angiography

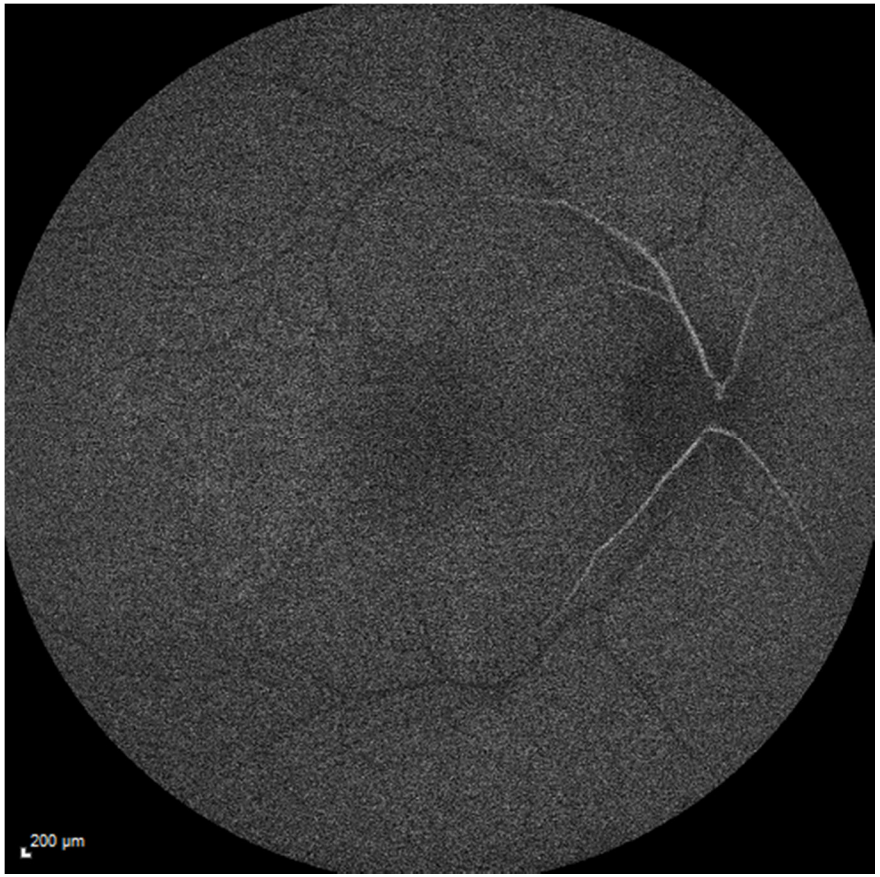

Other imaging modalities

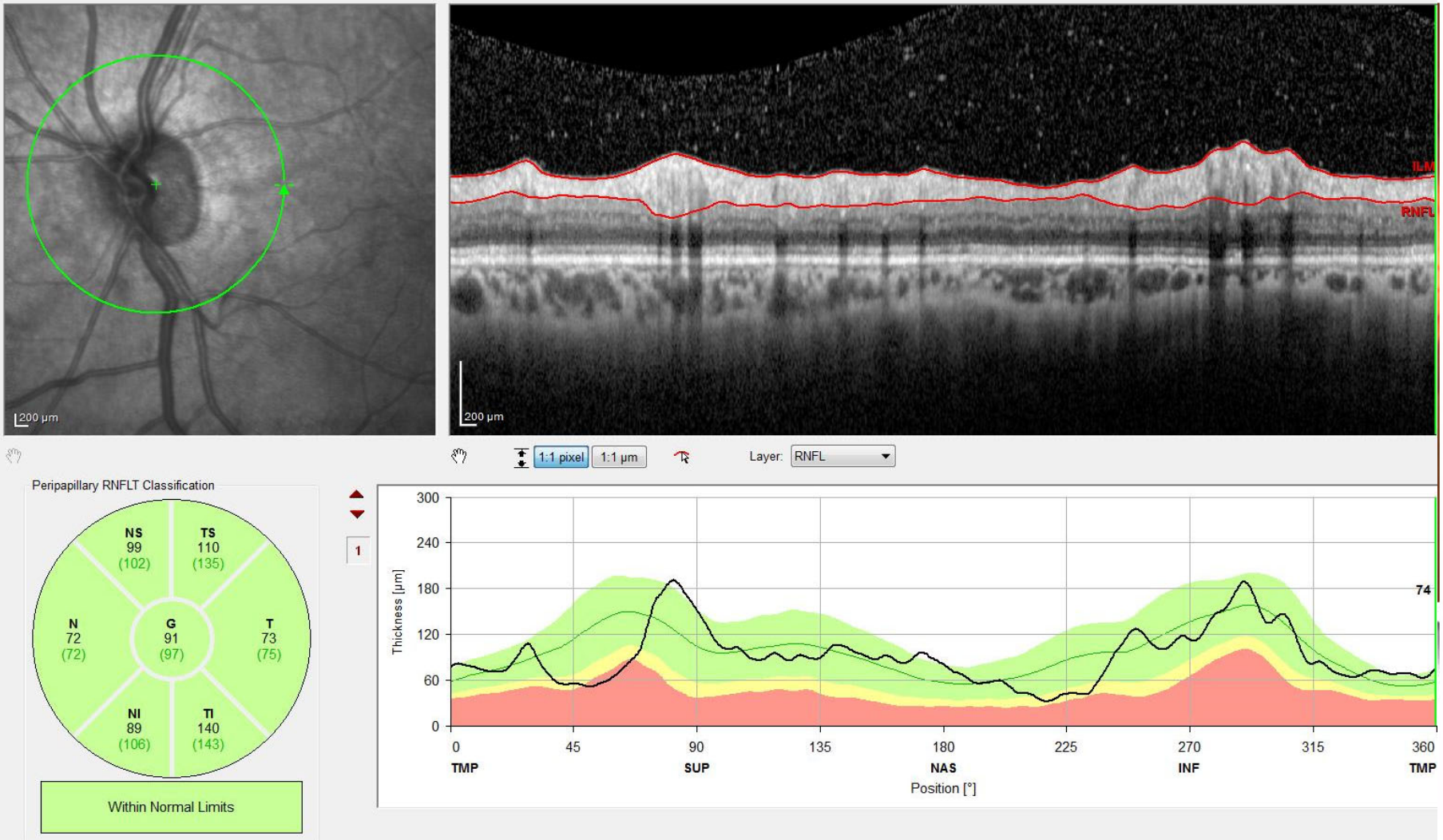

Other imaging modalities

- Ultrassonography (B-scan)

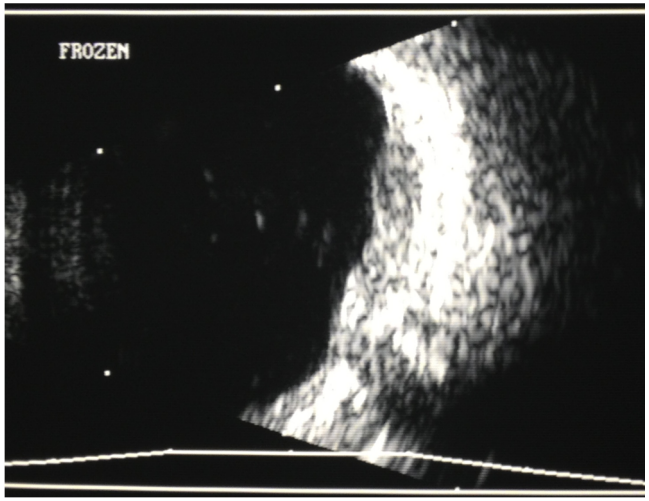

Increased vascular tortuosity

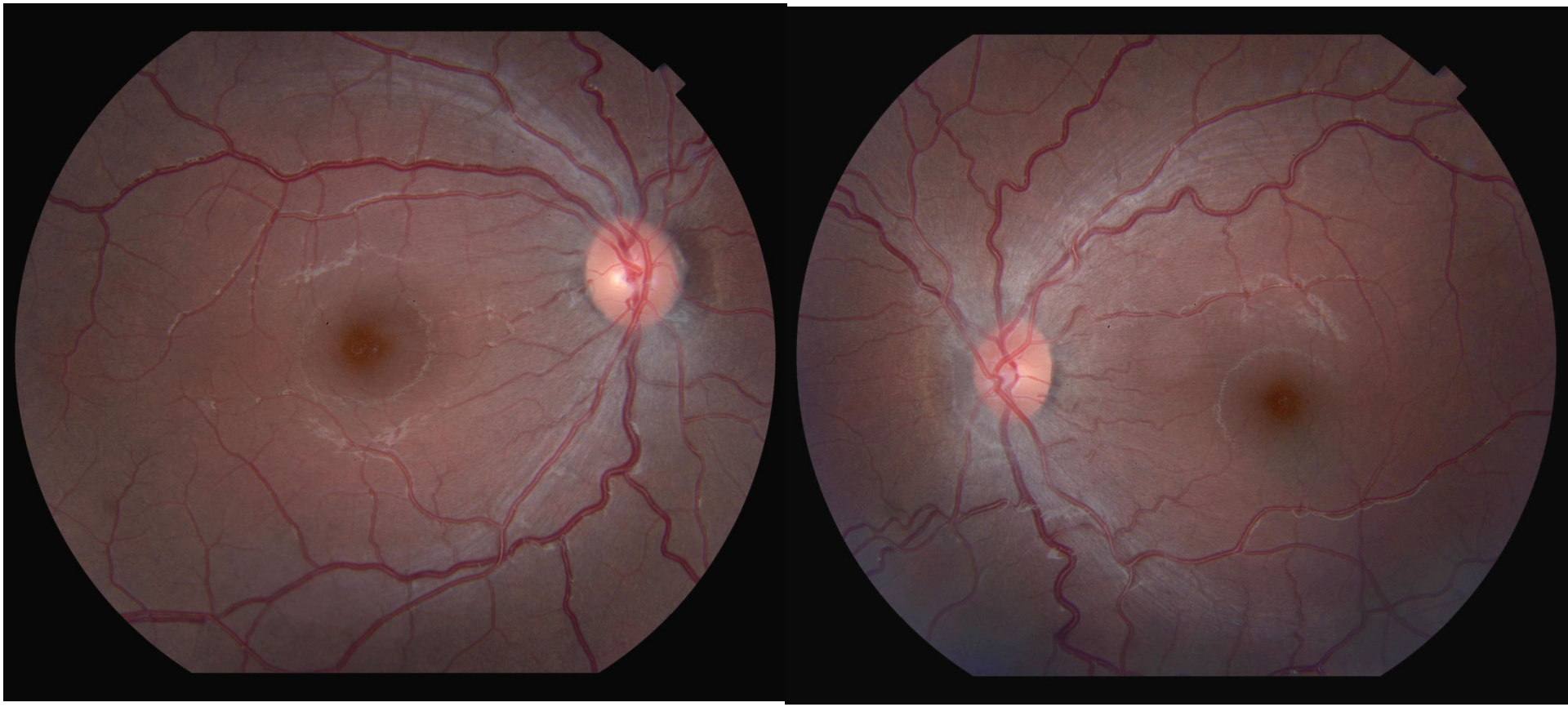

dvitor@ufmg.br

Disc sign

dvitor@ufmg.br

Salmon patch

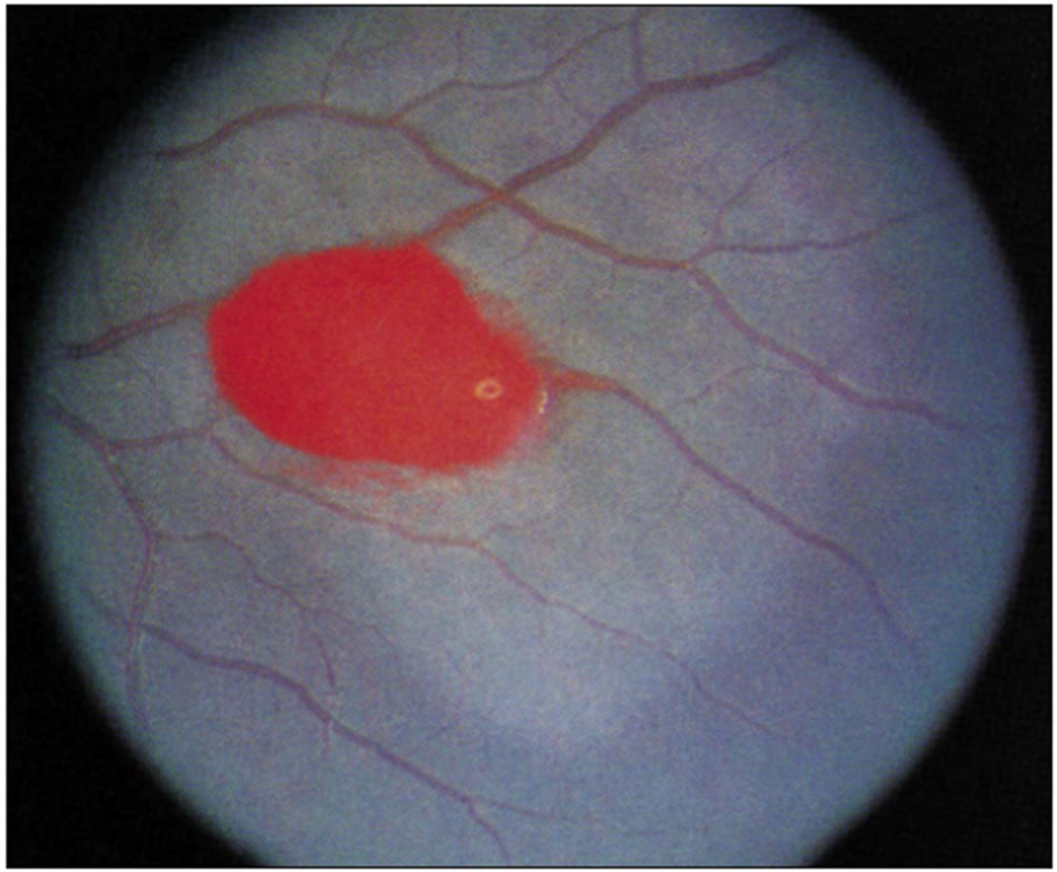

dvitor@ufmg.br

Black sunburst

dvitor@ufmg.br

Stage II

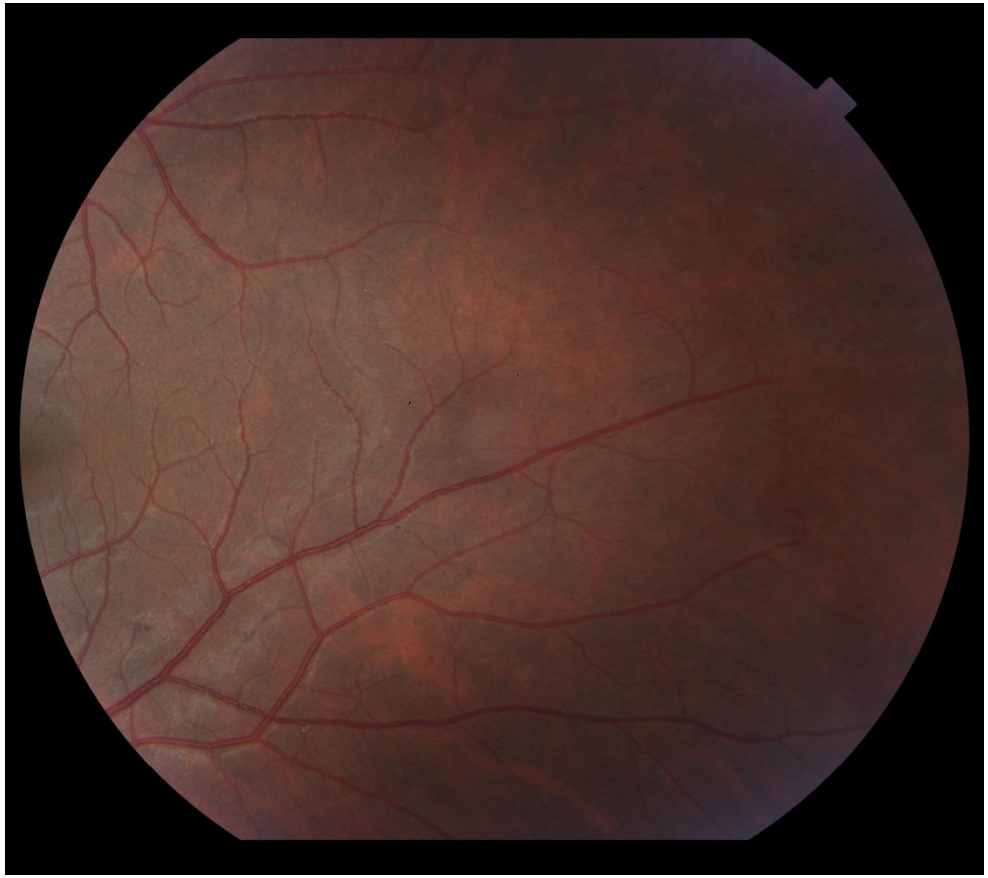

dvitor@ufmg.br

Stage III

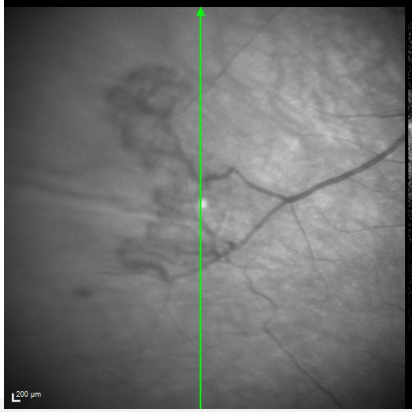

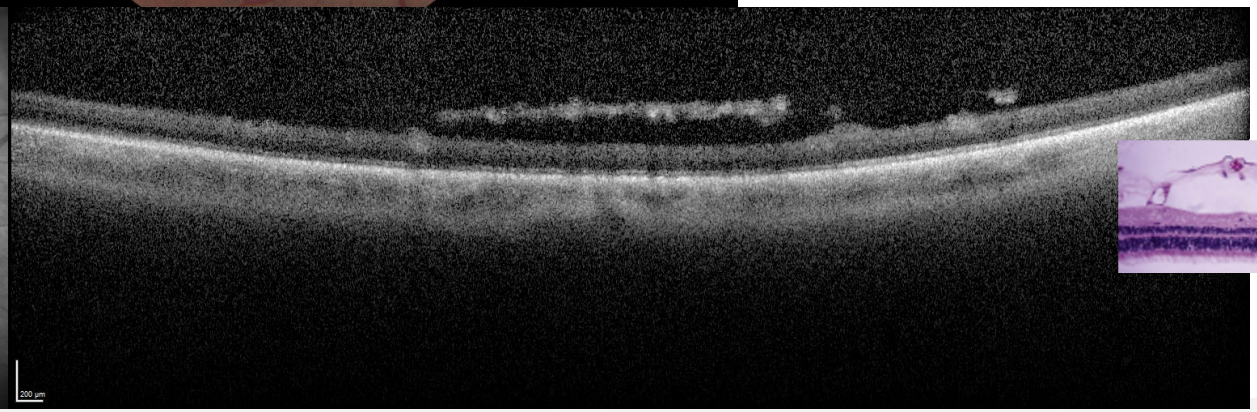

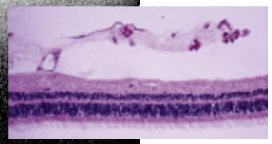

Stage III

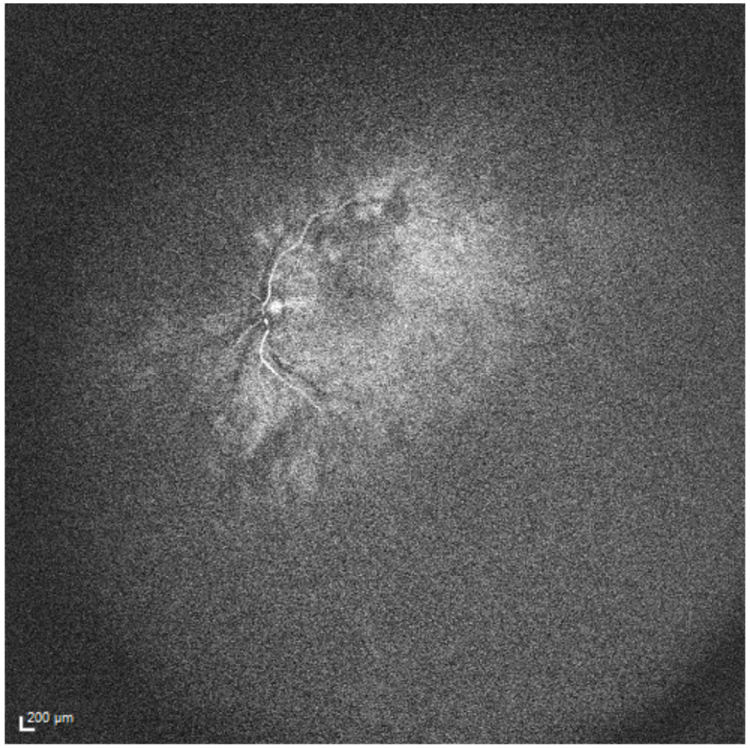

dvitor@ufmg.br

Stage III

dvitor@ufmg.br

Stage IV

dvitor@ufmg.br

Stage IV

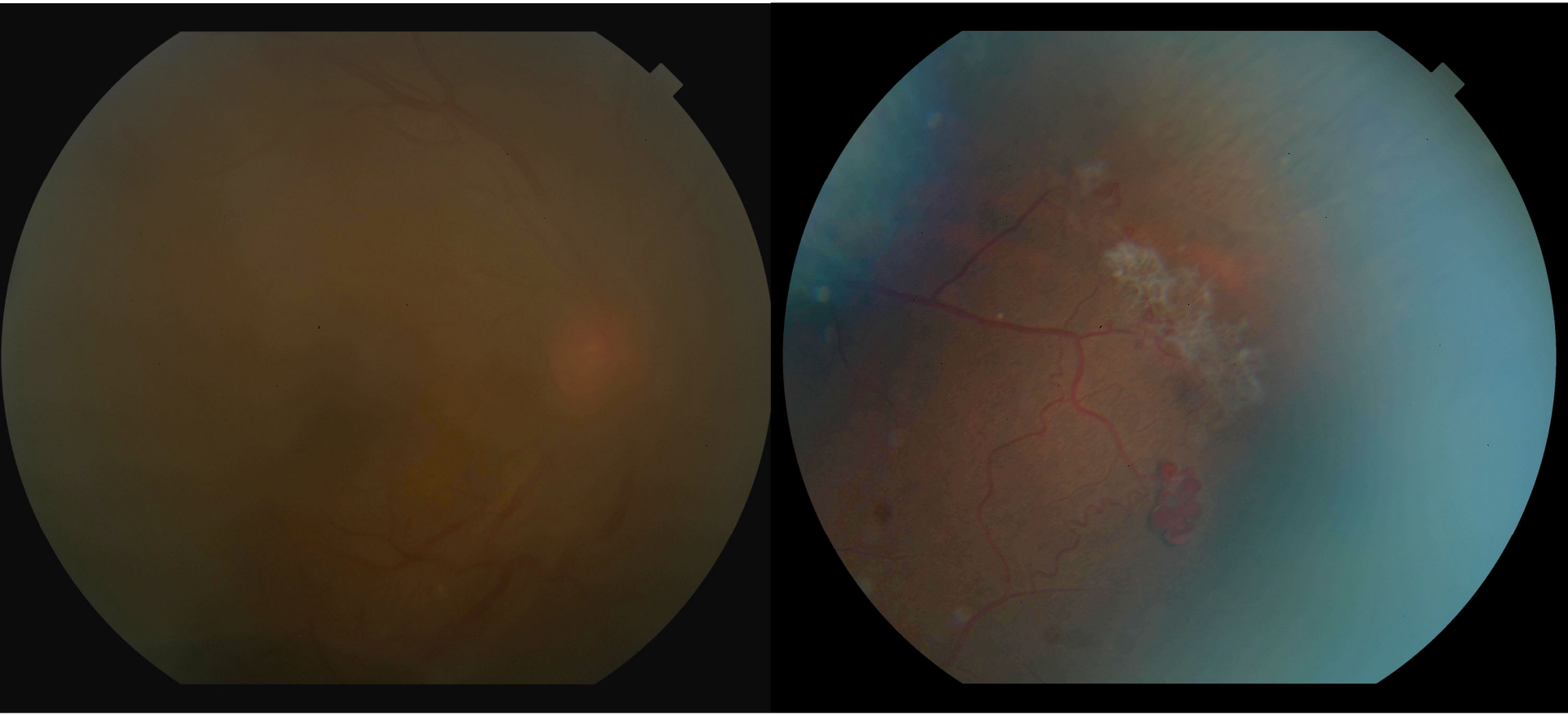

dvitor@ufmg.br

Stage IV

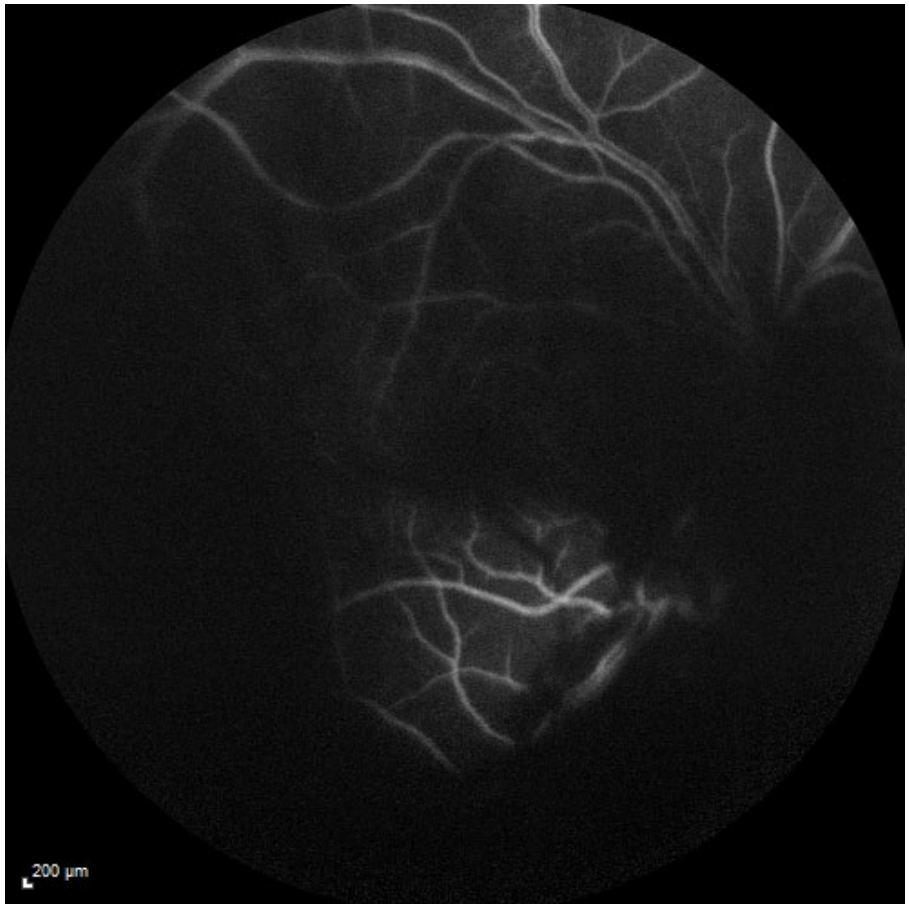

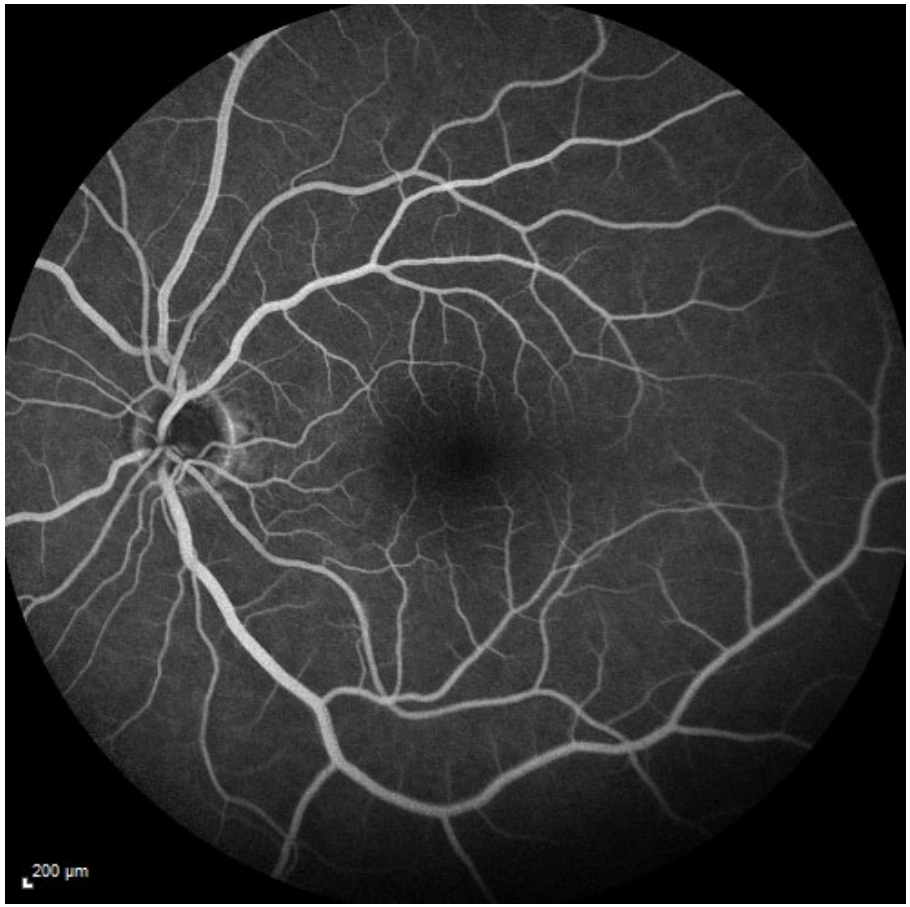

Stage IV

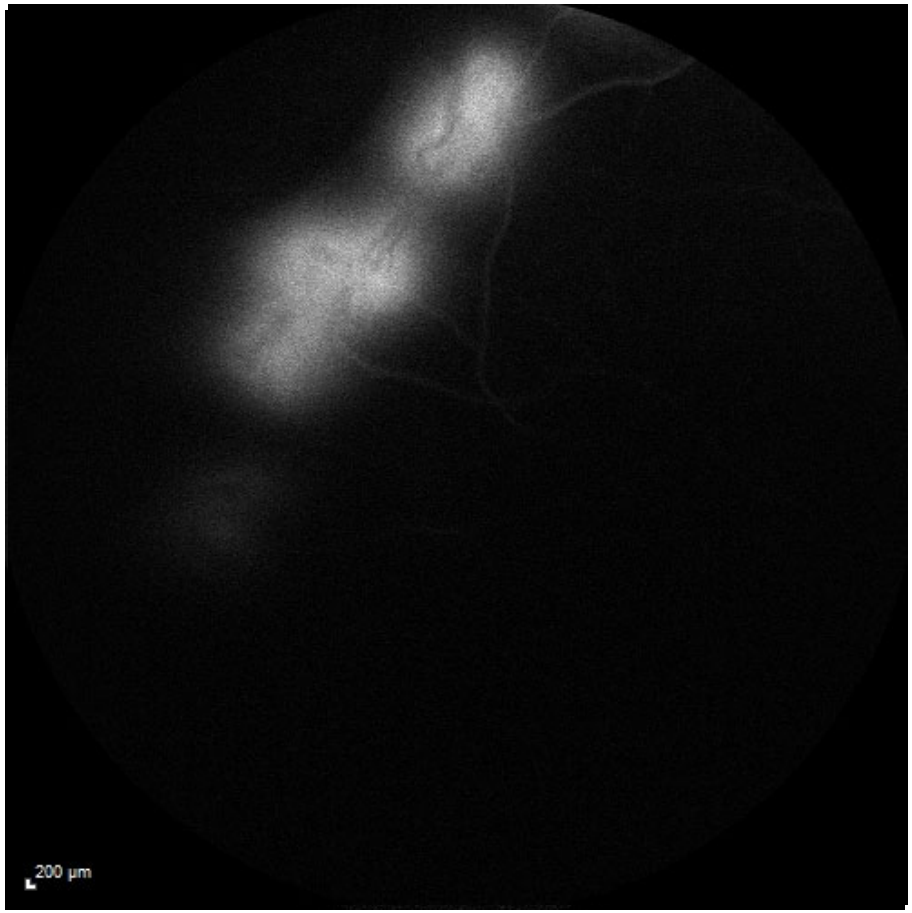

Stage IV

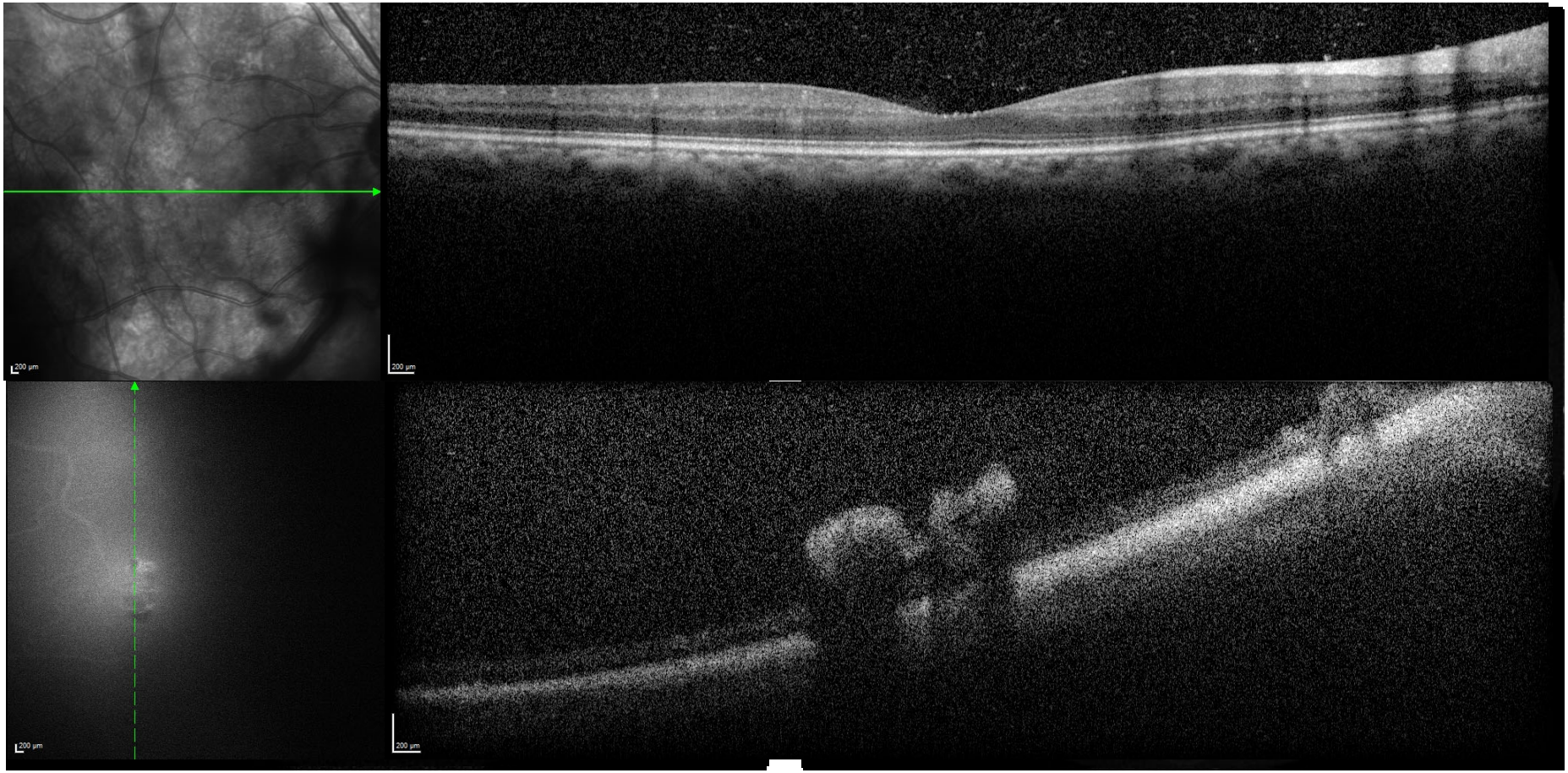

Stage V

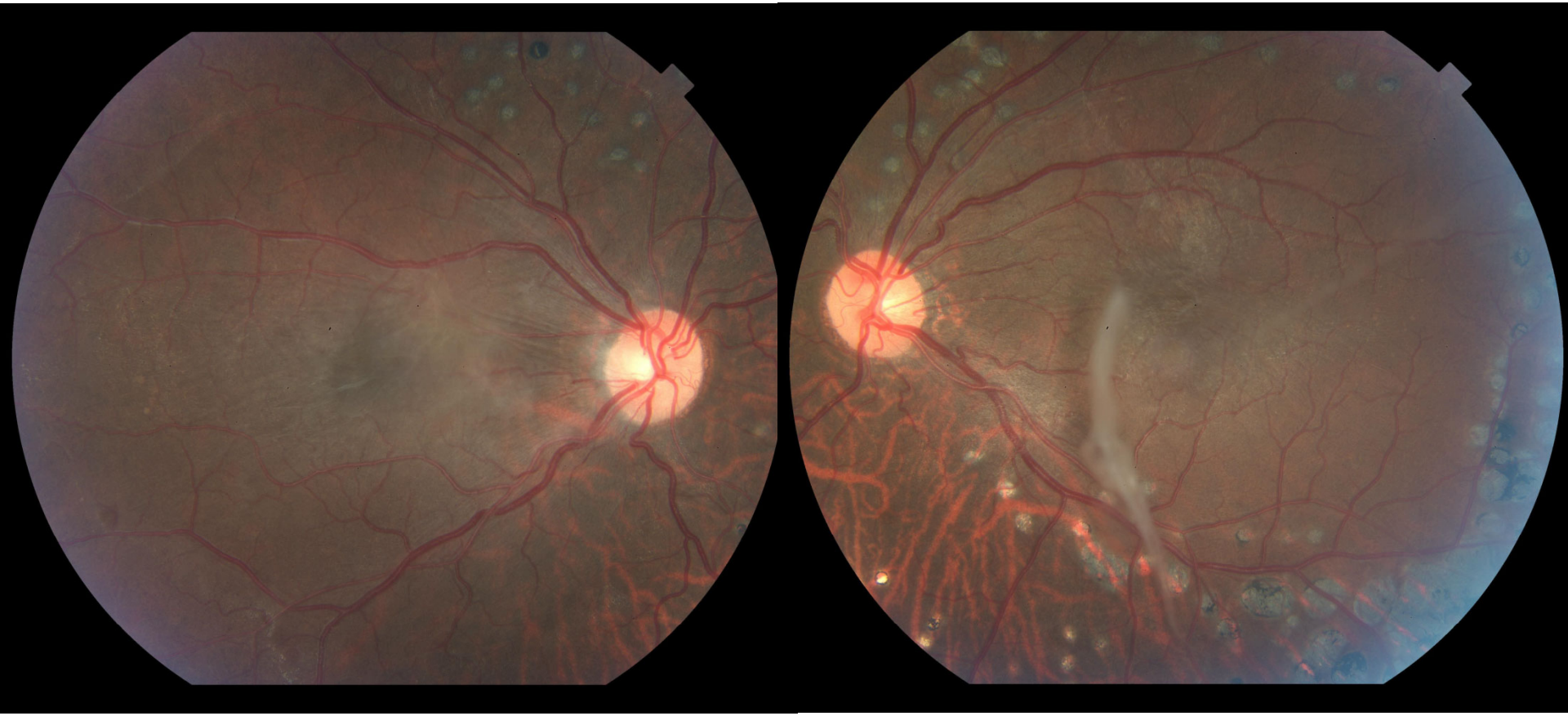

dvitor@ufmg.br

Stage V

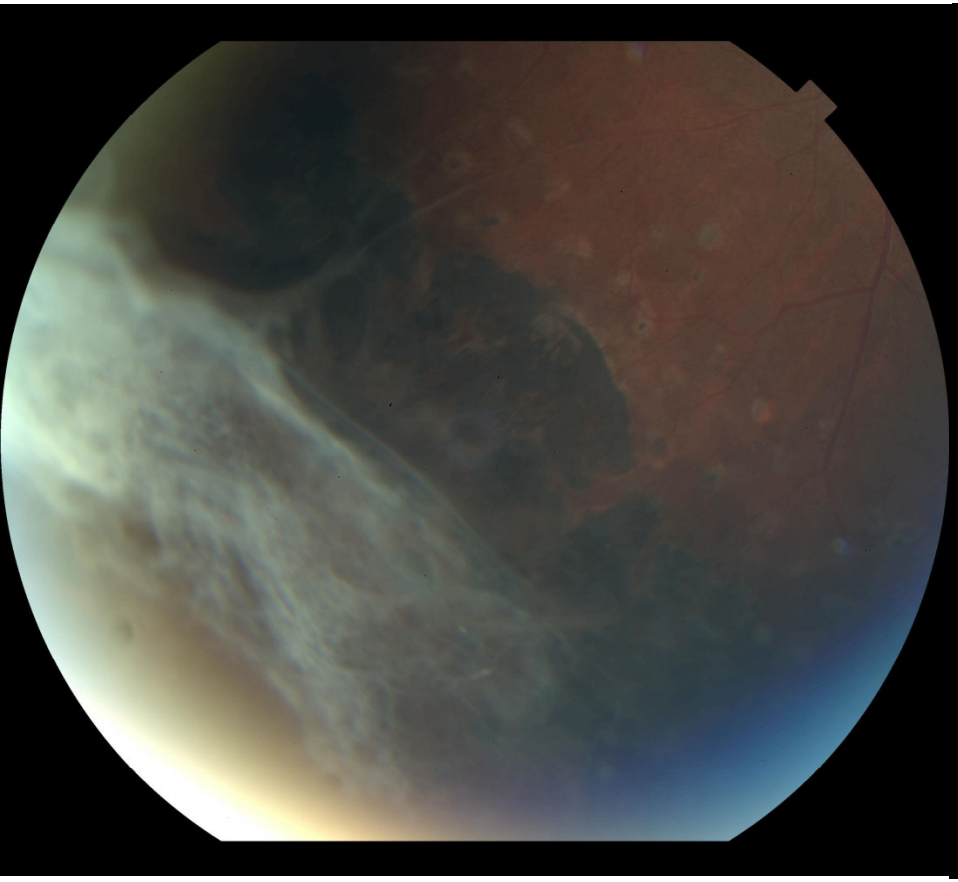

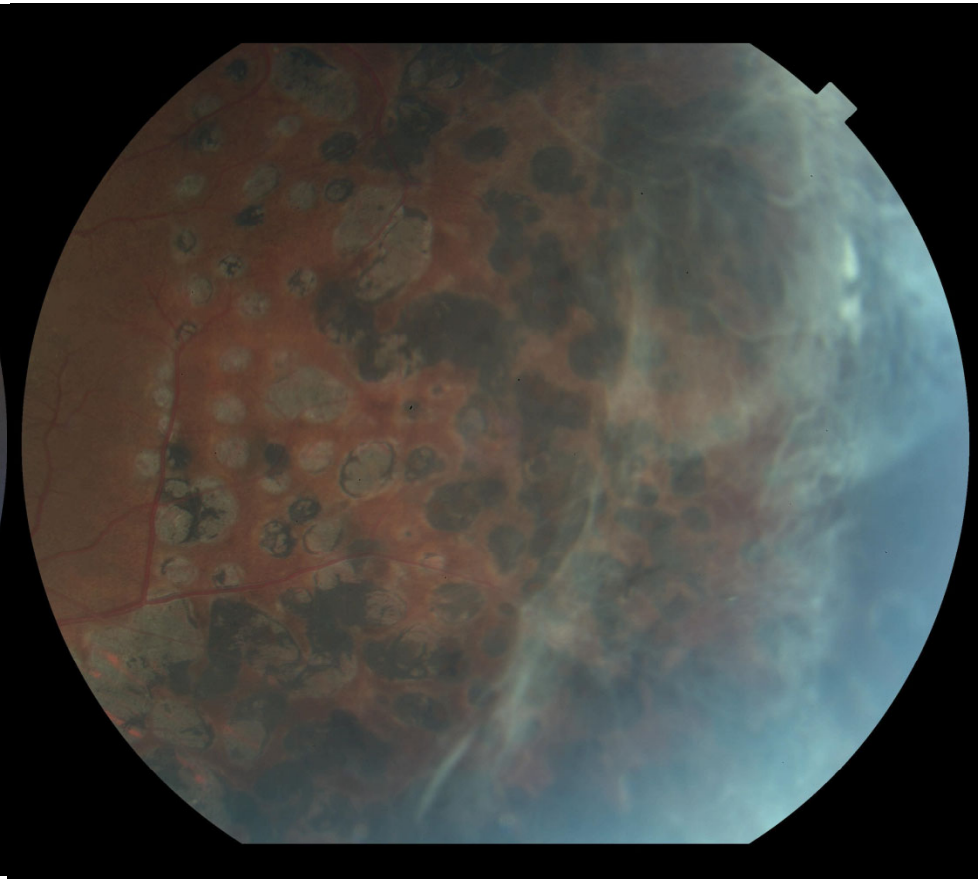

CONCLUSION

- High prevalence of sickle retinopathy
- Role of novel imaging modalities
- Importance of ophthalmologic examination
  - Peripheral “silent” lesions
  - No ocular symptoms
  - Risk of sight-threatening complications

dvitor@ufmg.br

ACKNOWLEDGMENTS

- CEHMOB / NUPAD team
- Hospital São Geraldo / HC-UFMG team
- HEMOMINAS team

dvitor@ufmg.br