SAÚDE DA MULHER

Caso Clínico

Luanna Rocha Vieira Martins

G.K.S.M, 17 years-old, HbSS, diagnosed with SCD since childhood, recurrent painful crisis

BASELINE DATA: Hg 7.2g/dL. WBC 17630mm^3. Saturation O_2 90%

PAST MEDICAL HYSTORY:

- History of recurrent vaso-occlusive crisis and acute chest syndrome in 2008, leading to hospitalization
- CHF since 07 years-old, but without medical supervision. Had been taking furosemide, captopril and spironolactone, discontinued in 2012
- She used Hydroxiurea until 2012, stopped use before pregnancy
- $G_2\ P_{N1}\ A_0$

-G1: at 16. Developed severe pre-eclampsia + fetal death with 06 months

PRENATAL OBH – 1st CONSULTATION: 13/09/2013

LMP: 07/07/2014 GA: 9w5d (did not do the US)

Chief complaint: dyspnea with medium activity

Reported Hypertension, due to elevated blood pressure, but without diagnosis

Use of folic acid

Last admission in September 2012, but she does not know the reason

Assessment: 1st trimester pregnancy + HbSS + bad obstetric history + CHF + Hypertension (?)

PRENATAL OBH: 27/09/2013

- GA: 11w5d (Cr: US 27/09/2013 with 11w)

Laboratory tests

- **Hb 7.4** Hct 21.9 MCV 86.7 Platelets 460.600 **Ret 6%**
- Creatinine Clearence 214; **24h proteinuria 1104**
- Urea 23 Creatinine 0,50
- DB 1.1 **IB 6.9** **AST 65** ALT 30 **GGT 120** **ALP 115**
- **LDH 1437**

Echocardiography

- 19/09/2013: Preserved biventricular systolic and diastolic function; mitral valve and tricuspid regurgitation. SPAP: 22 mmHg. Ef: 65%.

Assessement

- HbSS + bad obstetric history + nephropathy + CHF

PRENATAL OBH: 29/11/2013

- GA: 20w5d

- Patient attend to the clinic with a BP of 140x80 mmHg in 14/11/2013. Without complaints

- Physical Examination: BP 130X80 mmHg

- Assessment: HbSS + bad obstetric history + hypertension due to nephropathy

- Rigorous blood pressure curve and new tests were requested

PRENATAL OBH: 20/12/2013

- GA: 23w5d

- Blood Pressure Curve

- SBP: 120/150mmHg
- DBP: 70/90mmHg

- Physical Examination – BP 140X80mmHg

Laboratory Tests (12/12/13)

- Creatinine 0.4
- **24h Proteinuria 1979**
- **LDH 718**
- TGO/TGP 15/27 **Ret 7.7**

- Prescribed Nifedipine 20mg q12hr

PRENATAL OBH: 27/12/2013

- GA: 24w5d
- Patient reported headache after initiating Nifedipine
- Blood Pressure Curve:

- SBP: 130/160mmHg
- DBP: 80/100mmHg

- Physical Examination – BP: 160X70 mmHg
- Patient referred to outpatient for antihypertensive change

PRENATAL OBH: 08/01/2014

- GA: 26w3d. Patient admitted from 27/12/2013 to 02/01/2014 for blood pressure control. Use of Methyldopa 250 mg q8hr

- UTI treated with cephalexin during admission

PRENATAL OBH: 22/01/2014

- GA:28w3d

- Patient with an increase of blood pressure levels (BP 160X100mmHg two measures)

- Patient referred to the surgical unit

PRENATAL OBH: 06/02/2014

- GA: 30w5d. Patient returns after second admission (from 22/01 to 31/01/2014) with a diagnosis of superimposed preeclampsia. In use of Nifedipine 20 mg q8hr and Methyldopa 500 mg q8hr

- Corticotherapy in 23 and 24/01/2014. Prophylactic transfusion in 23/01/2014

Laboratory Tests (Admission)

- **23/01/2014:** Hb/Htc **8.1**/25.8 WBC 18600 (B 0%) Platelets 251400 **LDH 1785** Creatinine 0.6 TB/DB/IB 3.2/0.2/3.0 Uric Acid 7.4 TGO/TGP **105**/49 **Ret 10.8 albumine 2.9 ALP 383** GGT 57
- **24/01/2014**: **24h Proteinuria 4057**
- **29/01/2014**: Hb/Ht: **8.89**/24.8 WBC 17300 Platelets 321500 **LDH 1388** Creatinine 0.6 TB/DB/IB 2.0/1.3/0.7 Uric Acid 7.0 TGO/TGP 70/49

PRENATAL OBH: 12/02/2014 - Admission

Admission

- 31w3d, referred from Hemominas due to increased blood pressure (BP:160/100-220/100mmHg) during transfusion.
- The patient denied headache, scotomas and epigastric pain

Physical Examination

- BP: 170/100mmHG HR: 100bpm
- RS: Normal breath sounds. Eupneic
- AU: 29cm FHR: 148bpm
- P/V findings: cervix closed, uneffaced

Plan

- Monitoring. Initiated Nifedipine 20mg, MgSO4. Blood suply and new tests.

PRENATAL OBH: 12/02/2014 - Admission

- After discussion with the obstetrician, delivery was indicated due to severe preeclampsia

- Echocardiography: Preserved biventricular systolic and diastolic function; mitral valve and tricuspid regurgitation. sPAP: 22 mmHg. Slight enlargement of left atrium

- Patient submitted to c-section at 10 pm, male. 1295g, the newborn was admitted into the nursery. During the procedure, were administered 300 ml of packed red blood cells

PRENATAL OBH: 13/02/2014 - Admission

- Patient without complaints

- Change in medication:

- Nifedipine → Anlodipine /day10mg
- Methyldopa → Enalapril 20mg q12hr

EVOLUTION - Admission

- Patient progressed with increase of the blood pressure levels. Hydralazine 25mg q8hr.

- ECO (17/02/2014): sPAP: 50 mmHg. E_f: 59%. Slight Mitral valve and tricuspid regurgitation. Diastolic dysfunction grade 1 in left ventricle. Slight enlargement of left atrium.

- Tachypnea and ventilalatory-dependent chest pain in 20/02/2014: ACS? Thromboembolism?

- Initiated Cefepime and Azithromycin

- Increased Hydralazine to 50mg q8hr

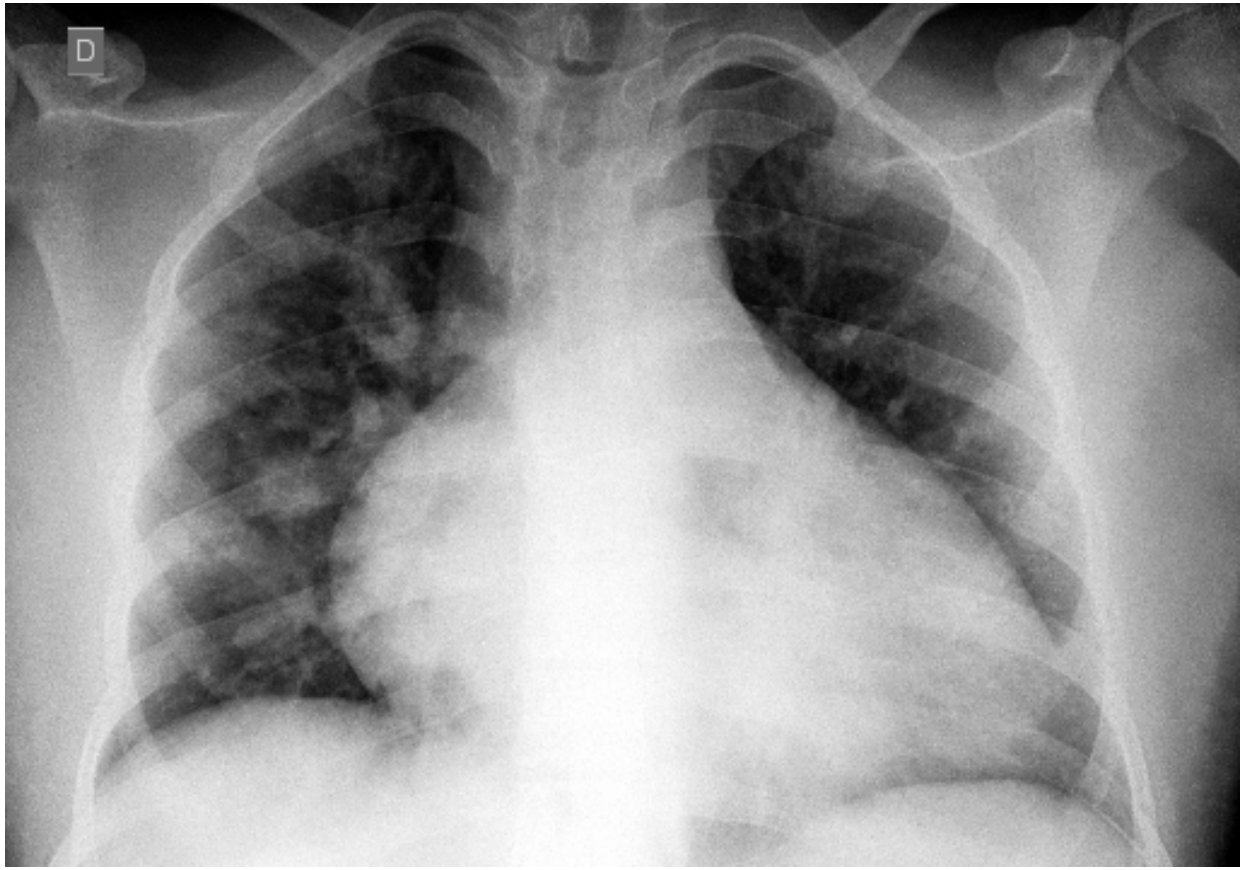

13/02/2014

EVOLUTION - Admission

- Clexane® was prescribed and the patient underwent exchange transfusion

- Chest radiography was normal
- Chest Angiotomography was requested

Laboratory Tests (21/02/2014)

- Hb/Ht **10.2**/29.8 Platelets 510000
- TB/DB/IB 0.6/0.4/0.2 **ALP 639 GGT 182**
- **LDH 1505** Creatinine 1.0
- TGO/TGP 28/16 **Ret 14.1**

- 22/02/2014: Angiotomography: no signs of thromboembolism, increase of cardiac area.
- Azithromycin→ Clarithromycin

EVOLUTION - Admission

- 24/02/2014: Duplex scan of lower limbs: no signs of DVT

- 03/03/2014: ECO: sPAP: 38mmHg. Ef: 62%. LA: 42mm. Diastolic dysfunction grade 1 in LV. Slight Mitral valve and tricuspid regurgitation

- Clinical improvement after 10 days using antibiotics

- Discharge: 05/03/2014

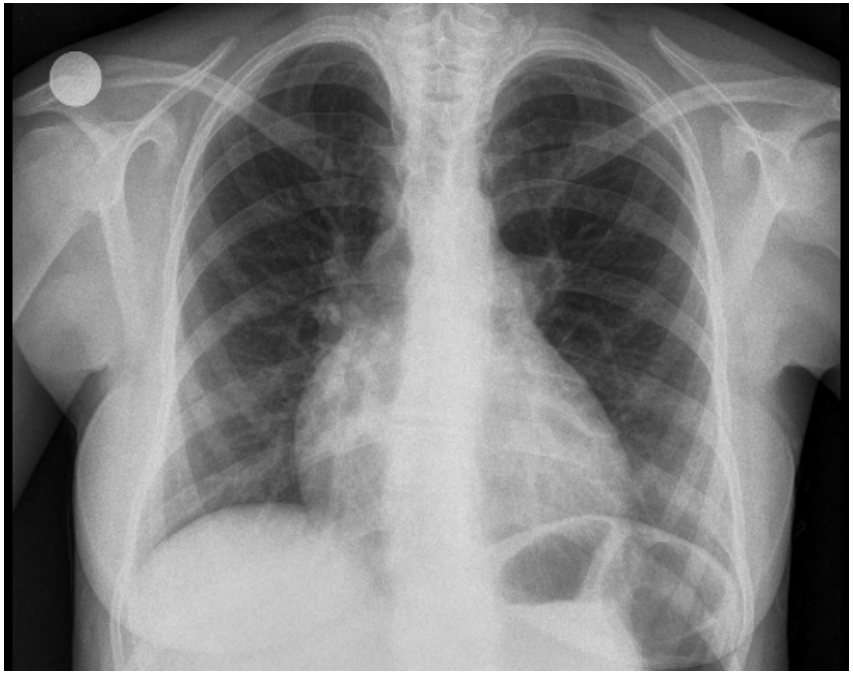

27/02/2014