OBSTETRICS

Clinical Report

Ana Flávia Dinardi Alves Pinto

GFS - 28 years old - Hb SC

She was attended at the blood Center, accompanied by her husband, with ten weeks pregnancy. G1 B0 A0. Desired pregnancy.

She complained of cough, mild dyspnea during one week and rhinorrhea. In use of Amoxicillin and Salbutamol spray, with some symptoms improvement .

Initiated prenatal care at basic health unit. Used Cephalexin for 7 days due to urinary tract infection.

Baseline data: Hb: 11,6 mg/dL WBC: 9600/mm^3
Menarche at 14 years old.
Attendance at Blood Center since 15 years old
Few painful crises. No history of blood transfusions
Proliferative retinopathy with performing laser 3 times

Clinical examination: BP 110/70 mmHg, clinically stable, eupneic, normal breath sounds, regular heart rhythm.

Hb 10 g/dL - WBC 10600/mm^3 - Platelet 436000/mm^3
Ferritin 77 µg /l - Proteinuria < 5 mg/dL - TGO 35 U - TGP 46 U
Creatinine 0,59 mg/dL - LDH 679 UI/L

Treated for sinusitis with symptom improvement.
Referred for high risk prenatal and Aninha Project

Asymptomatic until 22 weeks of pregnancy when developed hypertension (BP 140/90mmHg) and severe headache.

<u>Hospitalization:</u>

- **Maternal-fetal monitoring**
- **Obstetric ultrasound fetal doppler: severe IUGR, oligohydramnio and centralization flow. Fetal weight 263g**

- **Propaedeutics: proteinuria 24h 522 mg/day**

Hb 10 mg/dL - Hct 29% - Platelets 392 000/mm³
WBC 13 900/mm³ - LDH 841 UI/L
Uric Acid 4,9 - Creatinine 1,0 mg/dL - TGO 66 U TGP 46 U
Negative urine culture

Patient had a bad evolution with uncontrolled blood pressure levels despite the established medication, requiring interruption of pregnancy at 23 weeks. Expulsion of a dead fetus.

Pathological placenta of the dead fetus at the second trimester showed areas of ischemic necrosis and sickled erythrocytes in the chorionic villi vessels.

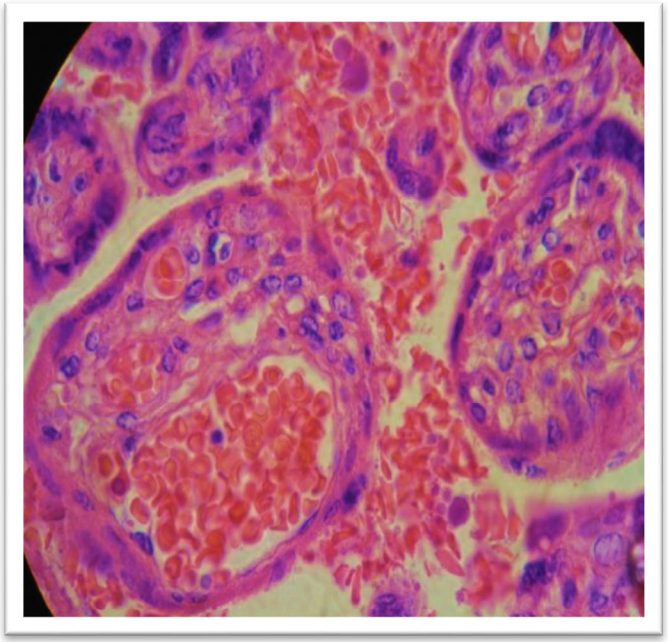

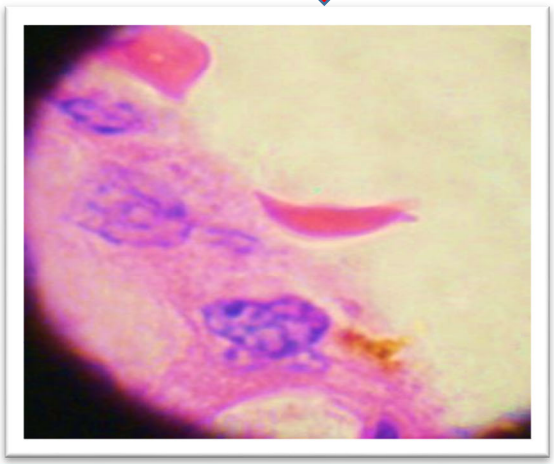

Flooded placenta by sickle erythrocytes

Postpartum: stabilization of clinical and blood pressure levels, did not require transfusions and was discharged after 6 days of hospitalization.

Puerperium: sinusitis treated as outpatients with antibiotics. Normal blood pressure level.

Advised to continue the treatment with a multidisciplinary team, including psychological support.

According to the outcome and considering the risk of serious complications in future pregnancies, the couple opted for permanent contraception. The husband had a vasectomy and they show willing for adoption.

DISCUSSION

How to assess the risk of a new pregnancy?

Reproductive counseling: How/ when/ by whom is it done?